

# The effect of ethanolic extract of mangosteen peel to malondialdehyde level, colony number, and pulmonary damage level score of tuberculosis model rats

*by* Indah Widyaningsih

---

**Submission date:** 29-Aug-2023 06:52PM (UTC+0700)

**Submission ID:** 2153405625

**File name:** hanolic\_extract\_of\_mangosteen\_peel\_to\_malondialdehyde\_level,.pdf (314.35K)

**Word count:** 3569

**Character count:** 19088

RESEARCH ARTICLE

1  
The effect of ethanolic extract of mangosteen peel to malondialdehyde level, colony number, and pulmonary damage level score of tuberculosis model rats

Indah Widyaningsih<sup>1,2\*</sup>, Sanarto Santoso<sup>3</sup>, Dwi Yuni Nur Hidayati<sup>3</sup>,  
23 santhy Djajalaksana<sup>1,4</sup>

<sup>1</sup>Doctoral Program of Medical Sciences, Faculty of Medicine, Brawijaya University, Malang 65145, Indonesia.

<sup>2</sup>Faculty of Medicine, Wijaya Kusuma University Surabaya, Surabaya 60189, Indonesia.

<sup>3</sup>Laboratory of Microbiology, Faculty of Medicine, Brawijaya University, Malang 65145, Indonesia.

<sup>4</sup>Department of Pulmonology, Saiful Anwar General Hospital, Malang 65111, Indonesia.

\*Corresponding Author E-mail: indahwidyaningsih31@gmail.com

ABSTRACT:

*Mycobacterium tuberculosis* is an intracellular pathogen that can replicate in host macrophages. This research examined the medication mechanism of mangosteen peel extract as anti-tuberculosis towards rats infected by *Mycobacterium tuberculosis* H37Rv. The mangosteen peel has chemical antituberculosis properties, such as xanthone, flavonoid, and tanin. Rats were infected by *M. tuberculosis* 10<sup>5</sup> (100 µl) by intratracheal for 4 weeks, then divided into 6 experimental groups: K1 (infected rats were treated by standard feed); K2 (infected rats were treated by INH); P1 (infected rats were treated by INH and extract 100mg/kg BW/day); P2 (infected rats were treated by INH and extract 200mg/kg BW/day); P3 (infected rats were treated by INH and extract 300mg/kg BW/day); and P4 (infected rats were treated by INH and extract 400mg/kg BW/day). INH and extract were administered orally for 4 weeks. On the 29<sup>th</sup> rats were euthanized to collect the left lung for MDA measurement and germs planting, and the right lung was collected for Hematoxyline eosin preparation. The data was analyzed by SPSS. The mangosteen peel ethanolic extract showed significant differences between treatments towards Tuberculous rats treated by INH. The MDA level decreased with a value of p=0,000 (p<0,005) r= 82,2% ; the decrease of colony count with a value of p=0,000(p<0,005) r= 93,3%; the decrease of pulmonary damage level score with p=0,001(p<0,005) r= 50%. Mangosteen peel ethanolic extract reduced MDA levels, colony counts, and lung damage levels at a dose of 200mg/kg BW/day of tuberculosis-model rats.

**KEYWORDS:** lung damage, malondialdehyde, *Mycobacterium tuberculosis*, MDA levels.

INTRODUCTION:

Tuberculosis is a global concern disease. Following the 2030 Sustainable Development Goals, WHO aims to reduce the tuberculosis mortal rate by 90% and reduce incidence by 80% in 2030 compared to 2014. In 2015 it is estimated that there are 10.4 million new cases of tuberculosis or 142 cases/100,000 populations, with 480,000 cases of multidrug-resistant.

Indonesia is a country with the second-largest number of new cases in the world after India. Sixty-percent of new cases occurs in 6 countries, including India, Indonesia, China, Nigeria, Pakistan, and South Africa. Mortal cases caused by tuberculosis are estimated at 1.4 million mortal cases plus 0.4 million deaths from tuberculosis in people with HIV. Although the mortal rate from tuberculosis decreased by 22% between 2000 and 2015, tuberculosis remained the 10th highest cause of death in the world in 2015. The increasing cases of drug resistance to tuberculosis have been reported where the cases of MRD TB in Indonesia are ranked number 8 from 27 countries with the highest MDR TB burden.<sup>1</sup>

The high incidence of tuberculosis in the world is caused by, among others, non-compliance with treatment

programs and inadequate treatments. Other various factors including lack of adherence to treatment, the emergence of multiple resistance, lack of resistance to micro bacteria, and reduced bactericidal power of existing drugs, and economic crisis increase the tuberculosis sufferer.<sup>2</sup> In Indonesia, there are recommended treatment regimens for National TB, such as Isoniazid (INH), Rifampicin (R), Ethambutol (E), pyrazinamide (P), and Streptomycin (S). Side effects that might likely happen after consuming these medicine are hepatotoxic, especially after consuming INH.<sup>3</sup>

*Mycobacterium tuberculosis* is an intracellular pathogen that can replicate in host macrophages. Nitric oxide (NO), Reactive Oxidative Intermediate (ROI), and Reactive Nitrogen Intermediate (RNI) produced by macrophages will destroy *M. tuberculosis*. Enzymatic antioxidants such as superoxide dismutase (SOD), Catalase (cat) will minimize damage to the tissue. The imbalance between the production of ROS and its antioxidant capacity will result in oxidative stress and disrupt fat, protein, and DNA. In general, TB is associated with an inflammatory process that will cause an increase in ROS and RNI. The production of ROS and RNI will induce fat peroxidation and cause the formation of malondialdehyde (MDA) which results in increased lung tissue damage.<sup>4</sup>

The potential of mangosteen peel extract as antibacterial, anti-inflammatory, and antioxidant with its active substance xanthone compounds ( $\alpha$ -mangostin,  $\beta$ -mangostin,  $\gamma$ -mangostin, mangostanol, garcinone A, garcinone B, garcinone C, mangostenol) shows the strongest activity. The three compounds strongly inhibited the growth of *M. tuberculosis* bacteria in vitro with a minimum inhibitory concentration of 6.25  $\mu$ g/ml,<sup>5</sup> and 31.25  $\mu$ g/ml. Previous research shows that the mangosteen peel (*Garcinia mangostan* Linn) ethanolic extract has chemical properties as an antioxidant, anti-inflammatory, anticancer, antibacterial, and can enhance the immune system of the body. The active ingredients of mangosteen peel include xanton, phenol, and flavonoids (antioxidants) which capable of reducing MDA levels.<sup>6</sup> This study was aimed to evaluate the effect of ethanol extract of Mangosteen peel towards the total colony, MDA levels, and damage level of tuberculosis rats' lungs.

## MATERIALS AND METHODS:

### Mangosteen Peel Ethanolic Extraction:

Simplicia materials were obtained from Batu Malang Materia Medika which had been identified. The maceration method was performed to obtain ethanolic extract of mangosteen peel using 96% ethanol solvent. Five-hundreds grams of simplicia soaked within 1.5 ethanol for 24 hours and stirred. The mixture was

filtered using a filter and vacuum extractor. The maceration filtrate was evaporated with a rotary evaporator until an 87.7-gram thick extract was obtained. Then thick condensation was dried in a drying cabinet for 24 hours. Then the extract was crushed and filtered.

Afterward, the active substance was identified by the spectrophotometer method in the Biochemistry University, Medical Faculty of Wijaya Kusuma University. This study was ethically approved with ethical clearance number 10198/SLE/FK/UWKS/2017.

### Animal model and study design:

This study was an experimental laboratory with post control only *M. tuberculosis* Isolate H37Rv obtained from the laboratory of Tuberculosis Tropical Disease Center Airlangga University Surabaya, which was cultivated on media Middlebrook 7H9. The animal objects, rats, were obtained from the Medical Faculty of Wijaya Kusuma University (male, weighed 150-200 grams). Rats were adapted in the laboratory for 2 weeks with a 40x60 size cage and containing 5 rats with standard feed and mineral water as needed.

After that, the rats were anesthetized subcutaneously with ketamine and xylazine (1: 1, 0.1 cc with ketamine 50 mg/kg BW and xylazine 50 mg/kg BW).<sup>7,8</sup> Then the rats were incised in the linea mediana region of the cervical region aseptically antiseptic until the trachea appeared, then injected between the tracheal rings by 100  $\mu$ l *M. tuberculosis* H37 Rv isolates from International Tropical Disease, Airlangga University. The wound was sutured back. Rats were returned to the cage and then treated standard feed for 4 weeks to prolong the infection.

After 4 weeks, the rats were divided into 6 groups. The drug used was isoniazid (INH) dose 300mg/kg BW/day. Where Laurence and Bacharach's tables were used for the conversion formula. The rats were divided into several experimental groups with different treatments. K1 received no treatments at all, K2 treated by isoniazid (300 mg/kg BW/day), P1 and treated by INH and ethanolic extract of Mangosteen peel 100mg/kg BW/day, P2 treated by INH and ethanolic extract 200mg/kg BW/day, P3 treated by INH and ethanolic extract 300mg/kg BW/day P4 treated by INH and ethanolic extract 400mg/kg/day.

The dosage was converted to Laurence and Bacharach tables. Afterward, the rats were euthanized on the 29<sup>th</sup> day using chloroform. The left lung organ was collected and placed formalin-containing pot for further histopathological preparation using Hematoxylin Eosin to observe the level of alveolitis lung damage,

bronchiolitis, vasculitis, and granuloma. The right lung was inserted into the physiological fluid for MDA level investigation using the ELISA method and TB bacteria colony using Middlebrook 7H10 media.

#### Histology Analysis with Hematoxylin Eosin Staining:

Ten-percent of Buffered Neutral Formalin (BNF) (pH 6.5 - 7.5) preparation. To prepare 1 liter BNF 10%, 4.0 grams of H<sub>2</sub>O, and 6.5 grams Na<sub>2</sub>HPO<sub>4</sub>. 2H<sub>2</sub>O dissolved within 1 liter of distilled water then 100 ml of formaldehyde (37%-40%) was added. Tissue fixation with the solution took place perfectly, then the comparison between organs and solutions was 1:10, the duration of fixation was at least 2 days.

The preparation of microscopic investigation started with the fixation of the left lung organ which had been immersed in a 10% BFN solution in PBS for two days then soaked. After the organ tissue that was in the fixative solution was mature, the tissue was drained on the filter then cut using a scalpel knife (0.3-0.5 mm) and arranged into a tissue cassette. The tissue cassettes were then put into a special basket, then dehydrated, vacuumed, paraffin blocks, cut paraffin blocks, then stained with Hematoxylin-Eosin.<sup>9</sup> All the samples were analyzed using Olympus light microscope with (M=22× and 400×).

#### Malondialdehyde and colony Examination:

Examination was performed by taking the right lung tissue and then crushed with a physiological solution and centrifuged to collect the supernatant. The supernatant was further investigated for Malondialdehyde using ELISA method with the Bioassay Technology Laboratory kit. The colony was examined by taking 100 µl and cultivated in the Middlebrook 7H9 growth medium for 2 weeks. Then moved to Middlebrook 7H10, read 4 weeks.

#### Data Analysis:

The results of histopathological examination of lung tissue from each treatment group were assessed using Dorman Score to determine the rats' lung damage level. The Dorman and Klopfleisch Score were based on histopathological observation results from these parameters: perialveolitis, peribronchiolitis, perivascularitis, and granuloma. Data were analyzed used SPSS 16.0 ANOVA (if data was not homogeneous and distributed normally) and Kruskal Wales (if the data was homogeneous/not homogeneous and not normally distributed), posthoc and regression statistical test was followed.

#### RESULT AND DISCUSSION:

The results of the mangosteen peel extract screening : Xanthon 3,86%,<sup>10</sup> Alpha mangosten 2,94%, Tanin 11,32%, Saponin, 4,91%. MDA levels in the treatment group were homogeneous and norm<sup>26</sup> distributed. After the ANOVA test was carried out to determine the effect of the concentration of mangosteen peel ethanolic extract on MDA levels, it was obtained that there was a significant effect between the concentration of extract with MDA levels (p=0.000). A Post-Hoc test was carried out with significant differences in mangosteen peel ethanolic extract between K1 and K2, P1, P2, P3, P4 groups, there were differences between K2 and K1, P2, P3, P4. Regression assay was used to determine the relation between these variables, the regression equation of MDA (X) = 0.003x<sup>2</sup> - 0.077x + 13.535 with R<sup>2</sup> = 82.2%. This meant that there was a significant relationship between the two variables at 82.2% (Table 1).

There were no bacterial colonies grow detected in the following groups: K2, P2, P3, and P4. The statistical test showed that the data was not homogeneous and was not normally distributed, so the Kruskal-Walis assay was carried out. It is obtained that there was a significant different effect between the concentration of extract and the number of colonies (p=0.000). This meant further tests were carried out so that K1 was found to be different from K2, P1, P2, P3, and P4; K2 was different from groups K1, P1, P2, P3, and P4; group P1 was different from groups K1, K2, P2, P3, P4; there was no difference between group P2, P3, P4. A regression assay was done to find the regression equation of Colony (X) = 5.625. 10<sup>-5</sup> x<sup>2</sup> - 0,035x + 5,063 with R<sup>2</sup> = 93.3%. This meant that there was a significant relationship between the two variables at 93.3% (Table 1).

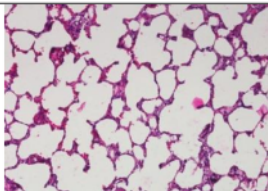
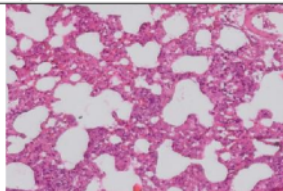
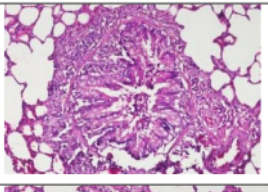
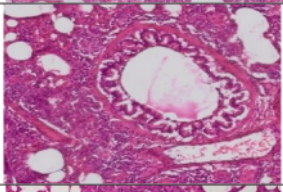
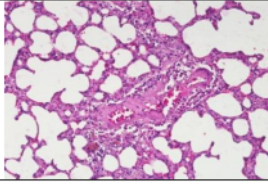
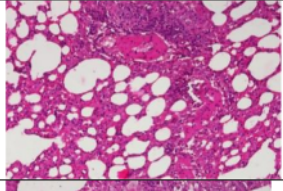

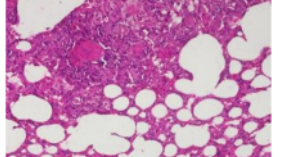
The level of pulmonary damage in the statistical assay was homogenous and not normally distributed. The Kruskal-Walis assay was carried out so that the value of p=0.032, this meant there was a significantly different treatment between the concentration of extract with the level of pulmonary damage. Further assays were carried out so that K1 was found to be different from K2, P1, P2, P3, and P4; K2 did not differ from the group, P1, P2, P3, and P4; Regression assay was done to find the regression equation of Level of pulmonary damage (X) = 3.75. 10<sup>5</sup> x<sup>2</sup> - 0.017x + 8.875 with R<sup>2</sup> = 50%. This meant that there was a significant relationship between the two variables at 50% (Figure 1).



Table 1. The effect of mangosteen peel ethanolic extract on MDA levels, CFU, pulmonary damage level score in Tuberculosis model rats

Variable	K1 M±SD	K2 M±SD	P1 M±SD	P2 M±SD	P3 M±SD	P4 M±SD
MDA ( $\mu\text{mol/ml}$ )	33.2±3.66	12.80±3.37	4.43±4.41	4.06±2.59	13.07±2.06	22.67±12.1
CFU	23.5±2.38	0	2.25±0.96	0	0	0
<b>Pulmonary Damage</b>						
Level Score	17.75±1	6.5±1.29	7.75±2.06	6.25±1.89	7.75±1.26	7.75±1.89

Table 2. The histopathological figure of pulmonary damage level in Tuberculosis rats which are treated INH and Ethanolic Extract of Mangosteen Peel

Tissues	Control	INH and Ethanolic Extract of Mangosteen Peel
Alveolus		
Bronchiolus		
Vascular		
Granuloma		

The score of Alveolitis, bronchiolitis, and vasculitis was as follows 0 to 5 where 0 was the absence of inflammatory cells; 1 = there were dominant PMN inflammatory cells; 2 = there were inflammatory cells with a thickness of less than 1 layer (less  $5\mu\text{m}$ ); 3 = There was an inflammatory cell with a thickness of 2 layers ( $5-10\mu\text{m}$ ); 4 = There were inflammatory cells with a thickness of more than 3 layers (more than  $10\mu\text{m}$ ); 5 = there were inflammatory cells and tissue damage. Whereas the granuloma score was 0 = no granuloma; 1 = there were granulomas in diameters of less than  $100\mu\text{m}$ ; 2 = granulomas with less than 2 sizes of diameter  $100-200\mu\text{m}$ ; 3 = There were granulomas in diameters of  $100-200\mu\text{m}$ , numbers of more than 2; 4 = granuloma more than  $200\mu\text{m}$ , number less than 2; 5 = There are granulomas in more than  $200\mu\text{m}$ , more than 2 (Table 2).

During tuberculosis infection the reactive oxygen species (ROS) and reactive nitrogen intermediates (RNI) are increased and produced as a consequence of phagocytic respiratory bursts. This ROS and RNI induce lipid peroxidation (LP), indicated by Malondialdehyde which is responsible for cell damage and can cause many pathological events.<sup>4,6</sup> This study showed that there was a decrease in MDA levels in the P2 group ( $200\text{ mg/kg BW/day}$ ), according to the study of the effect of adding morine to tuberculosis rats treated INH and Rifampicin. In the experimental group treated of INH and RIF in tuberculosis rats, MDA levels were higher than the combination of INH, RIF, and Morine.<sup>11</sup>

A decrease in MDA levels occurred in the P2 group (of  $200\text{mg/kg BW/day}$ ) and increased again with high doses due to the ethanolic extract of mangosteen peel being proxied. It was also found that the number of colonies decreased in tuberculosis rats treated INH and the

ethanolic extract of mangosteen peel in P2, P3, and P4 groups. INH also has a role in inhibiting the synthesis of mycolic acid which is a component that forms the cell wall of *M. tuberculosis*. INH inhibits the synthesis of mycolic acid through NADH-protein, acyl enoyl reductase encoded by *InhA*.<sup>12</sup> This research is following the research which reported that the growth of *M. tuberculosis* colonies exposed to INH is longer, the fewer the number of colonies formed.<sup>11</sup>

A decrease in pulmonary damage level indicated by alveolitis, bronchiolitis, vasculitis, and granuloma examinations, based on the Dorman and Klopfeisch method. The treated groups by INH and mangosteen peel ethanolic extract showed a decrease of pulmonary damage level best in the P2 group (200mg/kg BW/day). Pulmonary damage level score is influenced by levels of Malondialdehyde and the number of colonies. The treatment of INH and the mangosteen peel ethanolic extract showed a decrease in pulmonary damage level scores in P2 (200mg/kg BW/day) and an increase in scoring at high doses of 300mg/kg BW and 400mg/kg BW. This probably due to high doses of the effect of the extract being proxied according to the research.<sup>13</sup>

The administration of mangosteen peel extract for 4 weeks together with the administration of INH is very effective as an adjuvant. Because the most chemical compounds in mangosteen peel are: xanthone, phenols especially those containing tannin.<sup>14</sup> Tannin and flavonoids are very effective chemical properties in inhibiting the formation of bacterial walls. Xanthone contains alpha mangosteen and beta mangosteen and can activate the Protein Kinase enzyme so that it can inhibit free radicals, remind apoptosis process, suppress the necrosis process.<sup>15</sup>

Pulmonary tissue damage in Tuberculosis infection can be caused by bacteria inducing the MMP1 enzyme. Mustika reported that MMP 1 can be derived in the administration of herbal *Centella asiatica*. Crude *Garcinia mangostana* contains active substances that act as antioxidants can reduce the amount of mda at a dose of 200 mg/kg/day, but at higher levels will turn into prooxidants.<sup>16</sup>

## CONCLUSION:

This study concluded that 200mg/kg BW/day dose of mangosteen peel ethanolic extract can decrease the pulmonary damage. However, any higher dosage addition may cause an increase in pulmonary damage. Therefore, mangosteen peel ethanolic extract consumption must be standardized and avoided to give a higher dosage.

21

## ACKNOWLEDGMENT:

The authors would like to thank the Faculty of Medicine, Wijaya Kusuma University, and Center for Research and Consultation of Industrial Laboratorium Surabaya, East Jawa, for supporting this research.

19

## CONFLICT OF INTEREST:

There is no conflict of interest to be declared in this study.

## REFERENCES:

1. WHO. Tuberculosis. (online). Available from: URL: <http://www.who.int/mediacentre/factsheets/fs104/en>. [Accessed on March 10, 2017].
2. Ana S. Evaluasi Kepatuhan Penggunaan Obat Pada Pasien Tuberculosis Rawat Jalan di Balai Besar Kesehatan Paru Masyarakat Surakarta [Evaluation of the Compliance of Drug Use in Tuberculosis Outpatients at the Surakarta Lung Health Center]. Master Thesis, Muhammadiyah Surakarta University, Indonesia, 2012. [ID]
3. Indonesia Health Ministry. Pedoman Nasional Pengobatan Tuberculosis [National Guidelines for Tuberculosis Treatment]. Kementerian Kesehatan Republik Indonesia Direktorat Jendral Pengendalian penyakit dan Penyehatan Lingkungan. (online). Available from: URL: <http://www.doktemida.rekansejawat.com/dokumen/DEPKES-Pedoman-Nasional-Penanggulangan-TBC-2011-Doktemida.com.pdf>. [Accessed on March 14, 2017].
4. Adebimpe WO et al. Effects of treatment on free radicals in patients with pulmonary tuberculosis in South Western Nigeria. *African Health Science*. 2015; 15: 12: 6-61.
5. Suksamsaran S et al. Antimycobacterial activity of Prenylated Xanthones from the fruit of *Garcinia mangostana* Linn. *Chemical and Pharmaceutical Bulletin*. 2003; 51: 857-859.
6. Reddy YN et al. Role of free radical and antioxidant in tuberculosis patient. *Indian Journal of Tuberculosis*. 2004; 51: 213-218.
7. Warren J. Small Animal Anaesthesia. Mosby Co., USA. 1983.
8. Walter H. Hsu. Effect of Yohimbine and Xylazine-Induced Central Nervous System Depression in Dogs. *JAVMA*. 1985; 182(7): 698- 699.
9. Muntiha M. Temu Teknis Fungsional Peneliti [Technical meeting for functional researcher]. Balai Penelitian Veteriner, Bogor. 2001. [ID]
10. Widyarningsih I et al. Kandungan Xanton dalam ekstrak kulit manggis dengan pelarut etanol absolut [The content of Xanthone in mangosteen peel extract with absolute ethanol as solvent]. *Jurnal Ilmiah Pendidikan Eksha*. 2017; 3(2): 225-234. [ID]
11. Rawat R et al. The isoniazid-NAD adduct is a slow, tight-binding inhibitor of *InhA*, the *Mycobacterium tuberculosis* enoyl reductase: adduct affinity and drug resistance. *Proceedings of the National Academy of Sciences*. 2003; 100: 13881-6.
12. Zayni MMH and Abbas MT. Effect of morin on isoniazid and rifampicin induced hepatotoxicity in rats. *Kerbala Journal of Pharmaceutical Sciences*. 2018; 4: 32-39.
13. Fitri LE et al. High dose of N-acetylcysteine increase H<sub>2</sub>O<sub>2</sub> and MDA levels and decrease GSH level of HUVECs exposed with malaria serum. *Trends in Biomedicine*. 2011; 28: 7-15.
14. Yang C et al. Advances in isolation and synthesis of xanthone derivatives. *Chinese Herbal Medicines*. 2012; 4: 87-102. doi: [10.3969/j.issn.1674-6384.2012.02.003](https://doi.org/10.3969/j.issn.1674-6384.2012.02.003).
15. Pedraza-Chaverri J et al. Medicinal properties of mangosteen (*Garcinia mangostana*). *Food and Chemical Toxicology*. 2008; 46: 3227-3239.
16. Mustika A. Mekanisme ekstrak etanolik *Centella asiatica* (pegagan) dalam meningkatkan apoptosis sel alveolar makrofag dari jaringan paru tikus yang diinfeksi *M. tuberculosis* H37Rv [The mechanism of *Centella asiatica* (Centella asiatica) ethanolic extract in increasing apoptosis of macrophage alveolar cell from rat lung tissue infected with *M. tuberculosis* H37Rv]. Master Thesis, Airlangga University, Indonesia. 2012. [ID]

# The effect of ethanolic extract of mangosteen peel to malondialdehyde level, colony number, and pulmonary damage level score of tuberculosis model rats

## ORIGINALITY REPORT

14%

SIMILARITY INDEX

10%

INTERNET SOURCES

7%

PUBLICATIONS

9%

STUDENT PAPERS

## PRIMARY SOURCES

1	0barriers.com Internet Source	1 %
2	Submitted to Manipal University Student Paper	1 %
3	Submitted to Hong Kong University of Science and Technology Student Paper	1 %
4	Brown Holy, Ben-Chioma, Adline Erima, Idoko Roselin Adiza. "Oxidative Stress Markers and Selenium Levels of Pulmonary Tuberculosis Patients in Some Dot Centers in Port Harcourt", Journal of Advances in Medicine and Medical Research, 2018 Publication	1 %
5	Submitted to Universitas Sumatera Utara Student Paper	1 %
6	repository.unair.ac.id Internet Source	1 %

7	<a href="https://uknowledge.uky.edu">uknowledge.uky.edu</a> Internet Source	1 %
8	Ulfah Ulfah, Cicilia Windiyaningsih, Zainal Abidin, Farida Murtiani. "Faktor-Faktor yang Berhubungan dengan Kepatuhan Berobat Pada Penderita Tuberkulosis Paru", The Indonesian Journal of Infectious Diseases, 2018 Publication	1 %
9	<a href="https://faculty.uobasrah.edu.iq">faculty.uobasrah.edu.iq</a> Internet Source	1 %
10	Submitted to Universitas Muhammadiyah Surakarta Student Paper	<1 %
11	Submitted to International Islamic University Malaysia Student Paper	<1 %
12	Shylaja Dharmesh, Shashirekha Nanjarajurs, Shivaleela Bhimangouder, Mallikarjuna Eswaraiah, Rajarathnam Somasundaram. "Health and Wellness Product from Mangosteen (Garcinia mangostana L.) Rind: Bioactive Potentials", International Journal of Biotechnology for Wellness Industries, 2014 Publication	<1 %
13	<a href="https://www.mdpi.com">www.mdpi.com</a> Internet Source	<1 %



14

Susan M. Barlow, Claire Terry, Sean Gehen, Marco Corvaro. "Reproductive and developmental evaluations of triclopyr acid, triclopyr butoxyethyl ester and triclopyr triethylamine salt in the rat", Food and Chemical Toxicology, 2022

Publication

<1 %

15

Submitted to University of East London

Student Paper

<1 %

16

Submitted to Uttar Pradesh Technical University

Student Paper

<1 %

17

Vera Silva, Eva Gil-Martins, Bárbara Silva, Carolina Rocha-Pereira, Maria Emília Sousa, Fernando Remião, Renata Silva. "Xanthones as P-glycoprotein modulators and their impact on drug bioavailability", Expert Opinion on Drug Metabolism & Toxicology, 2021

Publication

<1 %

18

David A. Daunt, Eugene P. Steffey. "Alpha-2 adrenergic agonists as analgesics in horses", Veterinary Clinics of North America: Equine Practice, 2002

Publication

<1 %

19

[www.researchsquare.com](https://www.researchsquare.com)

Internet Source

<1 %

- |    |   |      |
|----|---|------|
| 20 | Shukla, S.. "Immunomodulatory activities of the ethanolic extract of <i>Caesalpinia bonducella</i> seeds", <i>Journal of Ethnopharmacology</i> , 20090907<br>Publication  | <1 % |
| 21 | Submitted to Universitas Jenderal Soedirman<br>Student Paper  | <1 % |
| 22 | <a href="http://nccur.lib.nccu.edu.tw">nccur.lib.nccu.edu.tw</a><br>Internet Source   | <1 % |
| 23 | Tri Yudani Mardining Raras, lin Noor Chozin. "The Soluble Plasminogen as a Biomarker on Monitoring the Therapy Progress of Pulmonary TB-AFB(+) Patients ", <i>Tuberculosis Research and Treatment</i> , 2010<br>Publication                     | <1 % |
| 24 | Yu Chen, Liyong Luo, Shanshan Hu, Renyou Gan, Liang Zeng. "The chemistry, processing, and preclinical anti-hyperuricemia potential of tea: a comprehensive review", <i>Critical Reviews in Food Science and Nutrition</i> , 2022<br>Publication | <1 % |
| 25 | Ming, M.. "Effect of the <i>Lycium barbarum</i> polysaccharides administration on blood lipid metabolism and oxidative stress of mice fed high-fat diet in vivo", <i>Food Chemistry</i> , 20090415<br>Publication                               | <1 % |

26

Waya Rahmaning Gusti Agrippina, Prihartini Widiyanti, Helmy Yusuf. "Synthesis and Characterization of Bacterial Cellulose - *Garcinia mangostana* Extract as Anti Breast Cancer Biofilm Candidate", Journal of Biomimetics, Biomaterials and Biomedical Engineering, 2017

Publication

<1 %

27

[pdfs.semanticscholar.org](https://pdfs.semanticscholar.org)

Internet Source

<1 %

28

[www.science.gov](http://www.science.gov)

Internet Source

<1 %

Exclude quotes Off

Exclude matches Off

Exclude bibliography Off