

Vol. 13 No. 3, September 2019

ISSN 1978-225X

# Jurnal Kedokteran Hewan



FAKULTAS KEDOKTERAN HEWAN UNIVERSITAS SYIAH KUALA

Bekerjasama dengan

PERHIMPUNAN DOKTER HEWAN INDONESIA



# Editorial Team

## Chief Editor

1. Prof. Dr. Drh. Tongku Nizwan Siregar, MP, Laboratory of Reproduction, Faculty of Veterinary Medicine, Syiah Kuala University, Indonesia

## Managing Editors

1. Drh. T Armansyah TR, M.Kes, Laboratory of Pharmacology, Faculty of Veterinary Medicine, Syiah Kuala University, Indonesia
2. Drh. Dwinna Aliza, M.Sc, Laboratory of Pathology, Faculty of Veterinary Medicine, Syiah Kuala University, Indonesia

## Associate Editors

1. Dr. Drh. Amalia Sutriana, M.Sc, Laboratory of Pharmacology, Faculty of Veterinary Medicine, Syiah Kuala University, Indonesia
2. Drh. Arman Sayuti, MP, Laboratorium of Clinic, Faculty of Veterinary Medicine, Syiah Kuala University, Indonesia
3. Drh. Budianto Panjaitan, M.Si., Laboratory of Clinic Faculty of Veterinary Medicine Syiah Kuala University, Indonesia
4. Dr. Drh. Hafizuddin, M.Si, Laboratory of Reproduction, Faculty of Veterinary Medicine, Syiah Kuala University, Indonesia

## International Editorial Board

1. Prof. Dr. Ömer Uçar, Division of Reproduction & Artificial Insemination, Department of Clinical Sciences, Muğla Sıtkı Koçman University, Turkey
2. Prof. Dr. Muchlisin Z.A, S.Pi, M.Sc, Faculty of Marine and Fisheries, Syiah Kuala University, Indonesia
3. Prof. Dr. rer. nat. A.M. Gunawan Indrayanto, Universitas Surabaya, Indonesia
4. Prof. Dr. Hasliza Abu Hassim, Department of Veterinary Preclinical Sciences, Universiti Putra Malaysia, Malaysia
5. Dr. Anuraga Jayanegara, S.Pt, M.Sc, Bogor Agricultural University, Indonesia
6. Prof. Dr. Noor Hashida Binti Hashim, University of Malaya, Malaysia
7. Prof. Dr. rer. nat. Rinaldi Idroes, S.Si, Faculty of Mathematics and Natural Sciences Syiah Kuala University, Indonesia
8. Dr. Mulyoto Pangestu, M.Rep.Sc., Department of Obstetrics and Gynaecology, Monash University, Australia
9. Asst. Prof. Dr. rer. nat. Sukanya Dej-adisai, Prince of Songkla University, Thailand
10. Prof. Dr. Ir. Samadi, M.Sc., Department of Animal Husbandry, Faculty of Agriculture, Syiah Kuala University, Indonesia
11. Dr. Elshymaa Ahmed Abdelnaby, BVM., DVM., MVSc., Theriogenology Department, Faculty of Veterinary Medicine, Cairo University, Egypt
12. Prof. Dr. Drh. Aulanni'am, DES, Faculty of Veterinary Medicine, Universitas Brawijaya, Indonesia
13. Dr. Alireza Ghaedi, Iranian Fisheries Research Institute, Iran, Islamic Republic of
14. Dr. Gholib, S.Pt., M.Si, Laboratory of Physiology, Faculty of Veterinary Medicine, Syiah Kuala University, Indonesia
15. Prof. Mst. Nahid Akter, M.Sc, Department of Aquaculture, Hajee Mohammad Danesh Science and Technology University, Bangladesh
16. Dr. Ma Asuncion Guiang Beltran, College of Veterinary Medicine, Tarlac Agricultural University, Philippines
17. Dr. Sharifah Rahmah, Universiti Malaysia Terengganu, Malaysia
18. Dr. Gaius Wilson, Victoria University of Wellington, and Provincial Health Services Authority, Vancouver, Canada

# Table of Contents

## Jurnal Kedokteran Hewan

PHYLOGENETIC ANALYSIS AND VIRULENCE-CODING GENES CHARACTERIZATION OF NEWCASTLE DISEASE VIRUS ISOLATED FROM LAYING HEN BRAIN WITH TETELO SYMPTOM

Safira Iqlima Sarah, Christian Marco Hadi Nugroho, Ryan Septa Kurnia, Dhandy Koesoemo Wardhana, Heni Puspitasari

[10.21157/j.ked.hewan.v13i3.14493](https://doi.org/10.21157/j.ked.hewan.v13i3.14493)

SEASONAL EFFECT ON SEMEN CHARACTERISTICS OF MURRAH BUFFALO BULLS RAISED UNDER TROPICAL CLIMATE

Nurul Isnaini, Tri Harsi, Devi Maharani

[10.21157/j.ked.hewan.v13i3.14627](https://doi.org/10.21157/j.ked.hewan.v13i3.14627)

STUDY OF *Coleus amboinicus* STEM EXTRACT IN INHIBITING MACROPHAGE CD-68 EXPRESSION IN WISTAR RATS WITH URIC ACID-INDUCED NEPHROPATHY

Rondius Solfaine, Wida Wahidah Mubarokah, Lailatul Muniroh

[10.21157/j.ked.hewan.v13i3.14266](https://doi.org/10.21157/j.ked.hewan.v13i3.14266)

CRYOPRESERVATION OF KAMPUNG ROOSTER SEMEN USING EGG YOLK DILUENT FROM FOUR TYPES OF POULTRY WITH DIFFERENT CONCENTRATIONS

Khairuddin Khairuddin, Muhammad Erik Kurniawan, Soman Soman

[10.21157/j.ked.hewan.v13i3.14892](https://doi.org/10.21157/j.ked.hewan.v13i3.14892)

FERTILITY AND FERTILE PERIOD OF DUCK EGGS AFTER ARTIFICIAL INSEMINATION WITH MUSCOVY DUCK SEMEN SUPPLEMENTED WITH VITAMIN C AND E

Nu'man - Hidayat, Ismoyowati - Ismoyowati, Chomsiatun Nurul Hidayah, Aras Prasetyo Nugroho

[10.21157/j.ked.hewan.v13i3.14694](https://doi.org/10.21157/j.ked.hewan.v13i3.14694)

## STUDY OF *Coleus amboinicus* STEM EXTRACT IN INHIBITING MACROPHAGE CD-68 EXPRESSION IN WISTAR RATS WITH URIC ACID-INDUCED NEPHROPATHY

Rondius Solfaine<sup>1</sup>, Wida Wahidah Mubarakah<sup>2\*</sup>, and Lailatul Muniroh<sup>3</sup>

<sup>1</sup>Department of Anatomy and Pathology, Faculty of Veterinary Medicine, University of Wijaya Kusuma Surabaya, Surabaya, Indonesia

<sup>2</sup>The Polytechnique of Agricultural Development Yogyakarta Magelang, Indonesia

<sup>3</sup>Department of Nutrition, Faculty of Public Health, Airlangga University, Surabaya, Indonesia

\*Corresponding author: wida\_wahidah02@yahoo.co.id

### ABSTRACT

The purpose of this study was to evaluate the effect of *Coleus amboinicus* stem extracts on uric acid-induced nephropathy by comparing the levels of Macrophage CD-68 expression and concentration of serum Cystatine C (CYS C) in Wistar rats (*Rattus norvegicus*). Twenty-four male Wistar rats with a body weight (bw) of 200-250 g, were allocated into three groups, with eight animals per group. The rats in control group (PO) received 0.1% carboxymethyl cellulose (CMC) solution orally. The rats in group 2 (P1) were orally induced with uric acid (UA) (500 mg/kg) and oxonic acid (OA) (750 mg/kg) and the rats in group 3 (P2) received uric acid (500 mg/kg), oxonic acid (750 mg/kg), and 500 mg/kg of the *Coleus amboinicus* stem extracts for 35 days. Bloods were collected for analysis of serum CYS C expression and concentration of serum creatinine and blood nitrogen urea (BUN). The rats in all groups were sacrificed for kidney tissue extractions for macrophage CD-68 identification and histopathology analysis. The levels of CYS C concentrations were analyzed by Avidin-Horseradish Peroxidase (HRP) sandwich-ELISA. The results showed that *Coleus amboinicus* stem extract at dose of 500 mg/kg bw significantly reduce BUN and creatinine levels ( $P \leq 0.05$ ), while Cys C levels were not different in group P2 compared with group P1. The activity of CD-68 (ED-1) macrophage decreased significantly ( $P \leq 0.05$ ) in group P2 compared to the control group and P1. Nephropathy induction using UA and OA causes severe kidney lesions characterized by degeneration, necrosis and inflammation of the renal tubules and glomerulus in the treatment group.

Key words: *Coleus amboinicus*, cystatine C, macrophage CD-68, nephropathy, uric acid

### ABSTRAK

Tujuan dari penelitian ini adalah mengevaluasi efek ekstrak batang *Coleus amboinicus* pada nefropati yang diinduksi oleh asam urat dengan membandingkan tingkat ekspresi makrofag CD-68 dan konsentrasi serum Cystatine C (CYS C) pada tikus Wistar (*Rattus norvegicus*). Dua puluh empat tikus jantan Wistar jantan dengan berat badan 200-250 g, dialokasikan menjadi tiga kelompok, delapan hewan tiap kelompok. Tikus dalam kelompok kontrol (PO) menerima 0,1% larutan carboxymethyl cellulose (CMC) secara oral. Tikus dalam kelompok 2 (P1) secara oral diinduksi dengan asam urat (UA) (500 mg/kg) dan asam oksonat (OA) (750 mg/kg) dan tikus-tikus pada kelompok 3 (P2) menerima asam urat (500 mg/kg), asam oksonat (750 mg/kg), dan 500 mg/kg ekstrak batang *Coleus amboinicus* selama 35 hari. Darah dikoleksi untuk analisis ekspresi serum CYS C dan konsentrasi kreatinin serum dan blood nitrogen urea (BUN). Tikus pada semua kelompok dikorbankan untuk ekstraksi jaringan ginjal untuk identifikasi makrofag CD-68 dan analisis histopatologi. Tingkat konsentrasi CYS C dianalisis dengan Avidin-Horseradish Peroxidase (HRP) Sandwich-ELISA. Hasil penelitian menunjukkan pemberian ekstrak *Coleus amboinicus* dosis 500 mg/kg bb dapat menurunkan kadar BUN dan kreatinin secara signifikan ( $P \leq 0.05$ ), sementara kadar Cys C menunjukkan perbedaan yang tidak signifikan. Pada kelompok perlakuan P2 dibandingkan dengan kelompok P1. Aktivitas makrofag CD-68 (ED-1) menurun secara signifikan ( $P \leq 0.05$ ) pada kelompok perlakuan P2 dibanding kelompok kontrol dan P1. Induksi nefropati menggunakan UA dan OA menyebabkan lesi ginjal yang ditandai dengan degenerasi, nekrosis dan peradangan tubulus ginjal dan glomerulus pada kelompok perlakuan.

Kata kunci: *Coleus amboinicus*, cystatine C, macrophage CD-68, nefropati, asam urat

### INTRODUCTION

Nephropathy is a kidney failure that as microscopically characterized by lesions varying from glomerulosclerosis, arteriosclerosis glomerular basement membrane thickening and mesangial cell proliferation. Nephropathy also related to nutrition such as hyperglycemia, hyperlipidemia and hypercholesterolemia. Pathogenically, nephropathy known to involve a variety of cell signaling systems, such as vasoconstrictor factors, inflammatory mediators, growth factors and adhesion molecules. Several methods for studying the pathogenesis of nephropathy has been developed to find an effective therapy, the compound induced nephropathy by way streptozotocine, cyclosporine, anthracyclines, electrolytes, ethylene glycol, cadmium, aminoglycosides, germanium dioxide, mercury chlorite, cisplatin and maleic acid (Balakumar *et al.*, 2008). While the method

of induction nephropathy by uric acid has been used both as a single agent or predisposing the formation of nephropathy (Kim *et al.*, 2000; Mazzali *et al.*, 2001; Shimada *et al.*, 2009; Kensara, 2013). Uric acid is the end product of purine metabolism to the role of the enzyme xanthine oxidase. Uric acid is broken down into compounds as soluble allantoin using uricase enzyme in the liver. But, in humans, there are gene mutations that have not the enzyme uricase, than uric acid cannot be broken down into allantoin and will potentially increase high uric acid levels in the blood. Uric acid is insoluble at the distal nephron, so that in the event of catabolism of purines in the body, uric acid distributed into tubules causing intrarenal precipitation, tubulointerstitial changes and glomerulosclerosis. In addition to the enzyme NADPH, uric acid oxidizes low density lipoprotein (LDL) to produce free radicals (ROS). The increase in free radicals will lead to the formation of arteriosclerosis, tubular atrophy,

interstitial fibrosis in kidney tissue, and inflammatory cell infiltration in glomeruli and interstitial of kidney tissue (So and Thorens, 2010).

Previously, study of uric acid-induced nephropathy revealed acute renal failure occurred due to deposition of urate crystals intrarenalis, tubular obstruction and inflammatory responses tubular and glomerular cells. Nephropathy in the rat, the expression of macrophage CD-68 known to play a role in renal inflammation and fibrosis in the epithelial cells of tubular and inhibits the expression of interleukin-1 $\beta$  gene induction of NF-kB (Zhou et al., 2014). With the induction of uric acid, it occurred deposition of urate crystals that damage the epithelial tubules which stimulates macrophage infiltration accompanied by expression of monocyte chemo attractant protein-1 (MCP-1) and induces the production of free radicals by mesangial cells (Roncal et al., 2007; Albertoni et al., 2012). Intratubular reported urate crystals also increased the expression of renin and cyclooxygenase-2 (COX-2), increased expression of MIF, the accumulation of tissue macrophages, lymphocytes T-cell infiltration, and expression of interleukin-2R (IL-2R), and MHC-II expression. Lesions were found in the form of conditions glomerulosclerosis, interstitial fibrosis and renal arteriosclerosis, and granuloma. Renin-angiotensin system is impaired is also a cause of hypertension (Kim et al., 2000; Mazzali et al., 2001; Kang et al., 2002). Intrarenal urate deposition induces inflammatory and fibrosis responses that interfere with the renin angiotensin system (RAS), stimulates the cyclooxygenase-2 (COX-2) enzyme and inhibits the nitric oxide synthase (NO) enzyme on endothelium (Lee et al., 2010). In diabetic nephropathy with hyperuresemia shows damage to pancreatic beta cells and damage to tubulointerstitial tissue (Kosugi et al., 2009).

The study of nephropathy with gout in experimental animals has almost the same pathogenesis in patients with nephropathy, namely acute renal failure with intrarenal urate crystal deposition, tubular blockage and inflammatory response. Moleculary, nephropathy by gout in white rats shows inflammation and fibrosis of tubular epithelial cells by increasing expression of Transforming Growth Factor- $\beta$ 1 (TGF- $\beta$ 1) and expression of Interleukin-1 $\beta$  (Song et al., 2009; Zhou et al., 2015). The deposition of urate crystals in the tubular epithelium causes macrophage accumulation and Monocyte Chemo attractant Protein-1 (MCP-1) expression accompanied by an increase in free radicals by mesangial cells, increased RAS, cyclooxygenase-2 (COX-2), MIF expression, lymphocyte cell infiltration, expression of Interleukin-2R (IL-2R) and expression of MHC-II (Roncal et al., 2007; Albertoni et al., 2012). Histologically, nephropathy shows glomerulosclerosis lesions, interstitial fibrosis, renal arteriosclerosis, and granuloma (Kim et al., 2000; Mazzali et al., 2001; Kang et al., 2002). The *Coleus amboinicus* plant is known to have been used as a cure for heat, cough,

bronchitis, sore throat, diarrhea and dysentery and food supplements for some people in Africa, Asia, Australia, and South America (Rice et al., 2011).

Genetically, *Coleus amboinicus* plant consists of 62 species and the types of plants studied as medicinal ingredients are *Coleus* or *Plectractus amboinicus* species. The active compounds from the leaves and stems of *Coleus* include monoterpenoid, sesquiterpenoid, diterpenoid, phenolic, squalene, caryophyllene, phytol, alkaloids, glycosides, flavonoids, quinones, tannins, and terpenoids (Lukhoba et al., 2006; Patel et al., 2010a; Pillai et al., 2011; Soni and Akhlesh, 2012). The stem of *Coleus amboinicus* contains quercetin flavonoid compounds (26.6 mg RE/g extract), which are marker compounds, and rosmarinic acid (6,160 mg/g extract), these two compounds are reported to inhibit the expression of interleukin and tumor necrosis factor- $\alpha$  in acute inflammation of Wistar rats (El-Hawary et al., 2012; Bhatt et al., 2013) and diuretic activity in the induction of Wistar white mouse nephrolithiasis (Jose and Janardhanan, 2005; Patel et al., 2010b). In addition extracts can also reduce serum urea, creatinine and uric acid levels and increase neutrophil activity, granulocytes, and platelet levels, antioxidant activity, anti-platelet aggregation, antibacterial and antiproliferative activity against cancer cells in vitro (Palani et al., 2010) is anti-inflammatory in the induction of rheumatoid arthritis Wistar rats (Chang et al., 2010), anticonvulsants (Bhattacharjee, 2010), anti-inflammatory and antitumor in vitro (Pavla and Gurgel, 2009). Therefore, this study was conducted to evaluate *Coleus amboinicus* stem extracts in inhibiting macrophage CD-68 expression and cystatin C (CYS C) concentration on uric acid-induced nephropathy in rat.

## MATERIALS AND METHODS

The research complies with the ethical clearance with the registration number No.518-KE from Animal Care and Use Committee (ACUC) Faculty of Veterinary Medicine Airlangga University, Surabaya, Indonesia. The research used twenty four Wistar rats (*Rattus norvegicus*) aged 2-3 months and weighed 200-300 g, which were allocated into three treatment groups (8 rats per group. All the rats were starved for 12 hrs before treatment. The rats in control group (P0) received 0.1% carboxymethyl cellulose (CMC) solution, while the rats in group 2 (P1) were induced with uric acid (500 mg/kg bw) and oxonic acid (750 mg/kg bw) to induce nephropathy. The rats in group P3 was also received uric acid (500 mg/kg), oxonic acid (750 mg/kg) and 500 mg/kg bw of *Coleus amboinicus* stem extracts. The treatment lasted for 35 days. At day 36<sup>th</sup>, the blood was taken via intra cardiac for analysis of serum creatinine (SC) and CYS C. Identification of CYS C concentration was performed using CYS C quantikine assay kit ELISA (Elabscience, Wuhan). This assay employed the quantitative sandwich enzyme immunoassay technique. A monoclonal antibody

specific for CYS C was pre-coated onto a micro plate, an enzyme-linked polyclonal antibody specific for CYS C. A substrate with color development was measured at 450 nm.

Renal function in the rats was evaluated using the colorimetric method (Creatinine and Blood Urea Nitrogen kit DiaSys Diagnostic Systems GmbH, Germany) to calculate the serum concentrations of blood urea nitrogen (BUN) and SC. This was conducted by measuring the changes in absorbance values after 1 min in the sample compared with the standard solution.

All rats in all groups were scarified by euthanized and renal tissue was collected. Half kidney was stored in 10 % formalin for histopathological examination and immunohistochemistry analysis for macrophage CD-68 identification. Expression of CD-68 was identified by indirect immunoperoxidase monoclonal antibodies (mAB) and secondary anti-peroxidase antibodies. The diamino-benzidine substrate was stained with immunohistochemical kits (BD, Pharmingen) and labeled streptavidin-biotin (LSAB) from Star Trek Universal HRP Detection (Biocare, USA).

Kidney tissue sections were examined in area of immunoreactive tubular cells under 100x and 400x magnification. The aspects in evaluating of CD-68 expression were positive reaction (brownish aggregate) or negative reaction (no colour of brown aggregate) of immunostaining, colour intensity and distribution of immunopositive cells. The percentage of tissue area were score 0 (if no alteration or normal cells), score 1 (has 1–30% positive cells), score 2 (has 31-50% positive cells), and score 3 (has 51-100% positive cells).

### Data Analysis

All the statistical analyses were processed using SPSS for windows (version 22). Values of the measured parameters were expressed as mean value  $\pm$  SD and the difference between the three group was determined using one way analysis of variance (ANOVA), and the significance was considered ( $P < 0.05$ ).

## RESULTS AND DISCUSSION

Serum creatinine levels in the control rats were within the normal range 0.20-0.80 mg/dL according to

Giknis and Clifford, 2008. Mean SC levels in Group P1 showed increased with an average SC of 0.69 mg/dL, which is a significant increase when compared with the controls. According to Roncal *et al.* (2007), creatinine levels in rats can increase after feed with 500 mg/kg bw uric acid and oxonic 750 mg/kg bw, while level of serum creatinine group P2 also increase significantly with average SC of 0.59 mg/dL (Table 1). Mean levels of blood urea nitrogen (BUN) in the control rats (P0) ranged from 28.65 mg/dL post treatment which was still within normal limits (10-58 mg/dL) (Giknis and Clifford, 2008). The group P1 showed significantly increased levels of BUN 41.22 mg/dL as long as groups P2 at 31.25 mg/dL after uric acid induction, compared with control rats ( $P < 0.05$ ; Table 1). According to Mazzali *et al.* (2001), oxonic acid and uric acid can cause renal damage characterized by elevated urea levels. Increased levels of urea in the treated are probably due to hypovolemic and dehydration as the early post-intra renal uric acid depositions response (Kang *et al.*, 2002).

Based on immunoassay measuring showed a statistically significant increase in the renal tissues levels of CYS C in uric acid-induced nephropathy rats in P1 and P2 group when compared to the control group, ( $P < 0.05$ ) (Table 2). Score of macrophage CD-68 expression was also significantly decreased in 1.38 the (P2 group) compared to the values found in the P1 group in score of 6.25. Expression of ED1-positive cells also seen in the renal tissue with uric acid-induced nephropathy in group P1 and P2, while no specific expression of ED1 in control group with score of 0.528 (Figure 1).

Based on standard tests to determine the status of kidney function is by measuring SC and BUN, but measurement of SC may not reflect the extent of the injury at kidney (Shimada *et al.*, 2009; Kensara, 2013). Nephropathy with uric acid-induced can be detected with a serum test, via level of CYS C expression. Blood urea nitrogen and SR clearance increased respectively, in nephropathy rats as compared with controls, indicating kidney disease with a decrease in glomerular filtration rate and renal tubular necrotic. The increasing of SC and BUN levels in this study were likely due to deposition uric acid intra renalis and a decreasing of renal function due to uric crystallization effects. In group P1 blood chemistry test results showed an increase in BUN and serum creatinine, whereas the

**Table 1.** Comparison of different serum levels of blood urea nitrogen (BUN) and serum creatinine (SC) on uric acid-induced nephropathy in various groups

Group	BUN (mg/dL)	SC (mg/dL)
Control	28.65 $\pm$ 2.39 <sup>a</sup>	0.51 $\pm$ 0.023 <sup>a</sup>
Uric-induced	41.22 $\pm$ 3.30 <sup>b</sup>	0.69 $\pm$ 0.051 <sup>b</sup>
Uric+ <i>Coleus amboinicus</i> extract	31.25 $\pm$ 2.64 <sup>c</sup>	0.59 $\pm$ 0.310 <sup>b</sup>

<sup>a, b, c</sup>Different superscripts within the same column indicate significant different ( $P < 0.05$ )

**Table 2.** Comparison of different score of number expression of macrophage CD-68 and concentration of cystatine C (CYS C) on uric acid-induced nephropathy in various group

Group	Macrophage CD-68	CYS C (mg/L)
Control	0.53 $\pm$ 0.53 <sup>a</sup>	0.74 $\pm$ 0.36 <sup>a</sup>
Uric-induced	6.25 $\pm$ 1.90 <sup>b</sup>	2.49 $\pm$ 0.90 <sup>b</sup>
Uric+ <i>Coleus amboinicus</i> extract	1.38 $\pm$ 5.18 <sup>c</sup>	2.61 $\pm$ 0.75 <sup>b</sup>

<sup>a, b, c</sup>Different superscripts within the same column indicate significant different ( $P < 0.05$ )

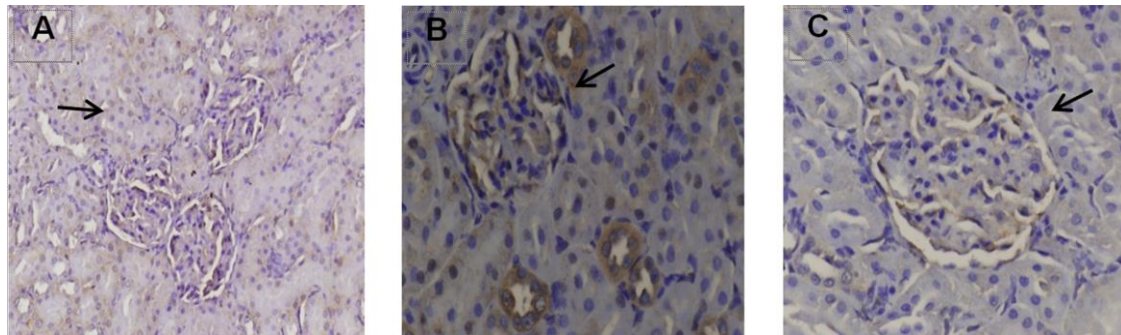


CYS C expression detection increased at 2.49 mg/mL. In P2 group with received of 500 mg/kg bw *Coleus amboinicus* extract no significantly increase expression of CYS C at 2.61 mg/mL when compared with the group P1 ( $P>0.05$ ). From previous study, CYS C was not only equal to BUN indicating the degree of kidney injury but also increased CYS C showed the renal damage significantly earlier than BUN. Furthermore, BUN levels are known to be strongly influenced by many non-renal factors such as protein intake, dehydration, gastrointestinal bleeding, infection or steroid use (Song et al., 2009). In this study, in group P2, expression of macrophage CD-68 is decreased with an average score of 1.38, which is a significant different at average score of 6.25 with group P1.

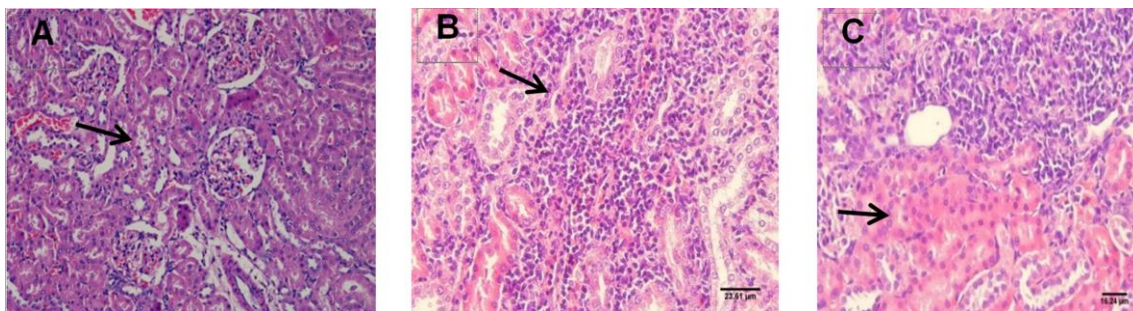
In the histopathological result showed there was a decreasing of renal function which indicated some tissue destruction such as vacuolization, cellular inflammation, necrosis in the area of the renal tubules, and forming of some sclerotic in glomerulus (Figure 2). PAS staining showed tissue thickening of Bowman

capsule in glomerulus and also thickening of renal tubules membrane (Figure 3).

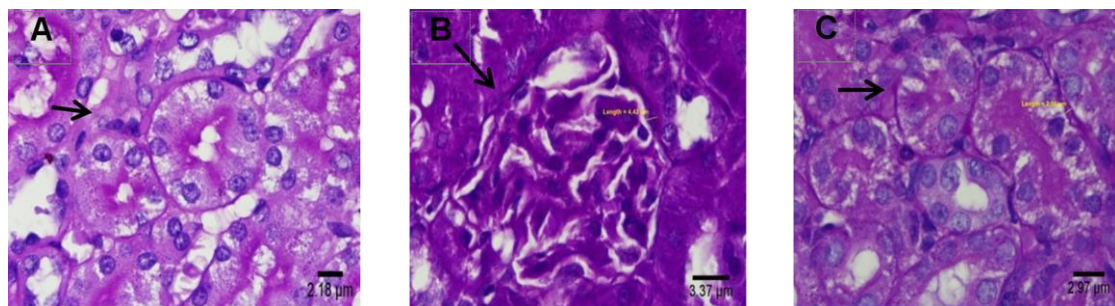
Feeding of *Coleus amboinicus* stem extracts significantly restored serum biochemical parameters to near control values in uric acid induced nephropathy rat which exceeds the control values. Treatment of nephropathy with medicinal plants, which has proved to be much safer than synthetic drugs, is an integral part of many cultures throughout the world and has gained importance in recent years. Medicinal plants contain a wide variety of free radical scavenging molecules, such as phenolic compounds, nitrogen compounds, vitamins, and some other endogenous metabolites, that are rich in antioxidant activity. From previous studies, which have demonstrated that polyphenols extracts of *Hibiscus sabdariffa* Linnaeus have been found to improve the renal function in experimental (Sefi et al., 2012). Treatment of uric acid and oxonic acid has produced toxic effects on the kidney by increase serum creatinine and level of BUN clearance in rats, our study showed level of SC and



**Figure 1.** Expression of ED1-positive cells in renal tissue. A= Control without treatment (P0), B= Uric acid-induced group (P1), C= Stem extract group (P2). Arrow indicate morphological change, immunohistochemistry, HE, 400x.



**Figure 2.** Morphological changes of vacuole degenerations and necrotic lesion on glomerulus and tubules with interstitial inflammations of plasma cells on tubules. A= Control without treatment (P0), B= Uric acid-induced group (P1), C= Stem extract group (P2). HE, 400x.



**Figure 3.** Thickening in Bowman capsule and membrane basal of tubules contortus. A= Control without treatment (P0), B= Uric acid-induced group (P1), C= Stem extract group (P2). PAS, HE, 400x

BUN were decrease in rats administered *Coleus amboinicus* stem extract when compare with P1 group. But mechanisms of *Coleus amboinicus* treatment in effect in uric acid-induced nephropathy rats are not yet cleared. These results also indicated that *Coleus amboinicus* stem extracts has the potential to repair the progression of renal dysfunction induced by uric acid apparently by preventing the morphological changes in the kidney. In uric acid-induced nephropathy rats, the increasing level of macrophage CD-68 was considered as a compensatory mechanism to protect kidney from the damage induced by free radicals. *Coleus amboinicus* content of phenol could reduce H<sub>2</sub>O<sub>2</sub>, lipoperoxides, and other organic hydro peroxides to their corresponding hydroxyl compounds using glutathione as a hydrogen donor. Activity of *Coleus amboinicus* phenol is up-regulated the H<sub>2</sub>O<sub>2</sub> and other ROS by reacting effectively with lipid and other organic hydro peroxides, and protecting against low levels of oxidant stress. Furthermore, phenolic contain of *Coleus amboinicus* extract appear to play a role in the GSH dependent defense against peroxynitrite-mediated oxidations, by serving as a peroxynitrite reductase (Sindhu et al., 2005; Noeman et al., 2011).

In this study, we used ED1 antibodies to detect the appearance and distribution of macrophages. ED1 antibody recognizes CD-68, which is located on phagosomes of blood monocyte-derived infiltrating macrophages and resident macrophages. ED1 expression implies enhanced phagocytosis. The number of ED1-positive cells increased in P1 group as long as P2 group at day 35. ED1-positive cells are likely to have phagocytic activity for cell debris after uric acid-induced nephropathy. Interestingly, compared with P1 groups positive cells, which the distribution of ED-positive macrophages was limited to the affected tubule epithelial and in glomerulus, suggesting differences in the slight distribution in interstitial tubules of ED-1 positive cells on P2 groups. The increased number of ED1-positive cells was consistently seen in P1 and P2 groups which uric acid-induced, in general agreement with the level of CYS C expressions (Figure 3).

Macrophages can be divided into three categories: blood monocyte-derived exudative macrophage, resident macrophage (Kupffer cells), and antigen-presenting dendritic cells. Recently, it has been reported that CD-68, the antigen recognized by ED1, functions as a scavenger receptor for hemoglobin haptoglobin complexes. The presence of CD-68 in lesions reflects the production of inflammatory mediators and clearing apoptotic material and producing growth factors during infection. Furthermore, macrophage plays a role in phagocytosis and produces toxic metabolites as well as proinflammatory cytokines such as IL-6 and TNF- $\alpha$  (Golbar et al., 2011; Nelson et al., 2012).

## CONCLUSION

The administration of *Coleus amboinicus* extract inhibits uric acid-induced nephropathy in winstar rat by

decreasing macrophage CD-68 expression and Cystatine C concentration.

## REFERENCES

- Albertoni, G.A., T.B. Fernanda, and S. Nestor. 2012. Uric acid and renal function. In **Diseases of Renal Parenchyma**. Sahay, M. (Ed.). In Tech, Rijeka, Brazil.
- Balakumar, P., A. Vishal, K. Vijay, J. Akash, R. Jayarami, and S. Manjeet. 2008. Experimental models for nephropathy. **J. Renin Angiotensin. Aldosterone. Syst.** 9(4):189-195.
- Bhatt, P., S.J.Gilbert, S.N. Pradeep, and C.V. Mandyam. 2013. Chemical composition and nutraceutical potential of indian borage (*Plectranthus amboinicus*) stem extract. **J. Chemistry.** 1:1-7.
- Bhattacharjee, P. 2010. Phytochemical and pharmacological investigation of different parts of *Coleus amboinicus* (Lour). **Thesis**. National College of Pharmacy. Rajiv Gandhi University of Health Sciences. Karnataka, Bangalore.
- Chang, J.M., C.M. Cheng, L.M. Hung, Y.S. Chung, and R.Y. Wu. 2010. Potential use of *Plectranthus amboinicus* in the treatment of rheumatoid arthritis. **Evid-Based Complementary Altern. Med.** 7(1):115-120.
- El-Hawary, S.S., H.E.S. Rabie, R.A.M. Azza, S.A. Rehab, and A.S. Amany. 2012. Polyphenolics content and biological activity of *Plectranthus amboinicus* (Lour.) spreng growing in Egypt (Lamiaceae). **Pharmacogn. J.** 4(32):45-54.
- Giknis, M.L.A. and C.B. Clifford. 2008. **Clinical Laboratory Parameters for CrI : WI (Han) Rats**. Charles river. USA.
- Golbar, H.M., T. Izawa, R. Yano, C. Ichikawa, O. Sawamoto, and M. Kuwamura. 2011. Immunohistochemical characterization of macrophages and myofibroblasts in  $\alpha$ -naphthylisothiocyanate (ANIT)-induced bile duct injury and subsequent fibrogenesis in rats. **Toxicol. Pathol.** 39(5):795-808.
- Jose, M.A. and S. Janardhanan. 2005. Modulatory effect of *Plectranthus amboinicus* lour on ethylene glycol- induced nephrolithiasis in rats cigarette smoke condensate reduces the detoxifying capabilities of rat. **Indian J. Pharmacol.** 37(1):43-44.
- Kang, D.H., N. Takahiko, F. Lili, H. Raymond, and J.J. Richard. 2002. A role for uric acid in the progression of renal disease. **J. Am. Soc. Nephrol.** 13(9):2888-2897.
- Kensara, O.A. 2013. Protective effect of vitamin c supplementation on oxonate-induced hyperuricemia and renal injury in rats. **Int. J. Nutr. Metab.** 5(6):61-66.
- Kim, Y.G., X.R. Huang, S. Suga, M. Mazzali, D. Tang, C. Metz, R. Bucala, S. Kivlighn, R.J. Johnson, and H.Y. Lan. 2000. Involvement of macrophage migration inhibitory factor (MIF) in experimental uric acid nephropathy. **Mol. Med.** 6(10):837-848.
- Kosugi, T., N. Takahiro, H. Marcelo, Z. Li, Y. Yukio, G.S.L. Laura, R. Carlos, J.J. Richard, and N. Takahiko. 2009. Effect of lowering uric acid on renal disease in the type 2 diabetic db/db mice. **AJP-Renal. Physiology.** 29:481-488.
- Lee, S., K. Won, P.K. Kyung, M.J. Kang, K.P. Sung, and J.K. Myung. 2010. Chronic urate nephropathy with a disproportionated elevation in serum uric acid. **NDT. Plus.** 3(3):320-321.
- Lukhoba, C.W., S.J.S. Monique, and J.P. Alan. 2006. *Plectranthus*: A review of ethnobotanical uses. **J. Ethnopharmacol.** 103(1):1-24.
- Mazzali, M., J. Hughes, Y. Kim, J.A. Jefferson, D. Kang, and K.L. Gordon. 2001. Elevated uric acid increases blood pressure in the rat by a novel crystal-independent mechanism. **Hypertension.** 38(110):1-6.
- Nelson, P.J., J.R. Andrew, D.G. Matthew, H. Jeremy, K. Christian, and D. Jeremy. 2012. The renal mononuclear phagocytic system. **J. Am. Soc. Nephrol.** 23(2):194-203.
- Noeman, S.A., E.H. Hala, and A.B. Amal. 2011. Biochemical study of oxidative stress markers in the liver, kidney and heart of high fat diet induced obesity in rats. **Diabetes. Metab. Syndr.** 3(17):1-22.
- Palani, S., S. Raja, R. Naresh, and B.S. Kumar. 2010. Evaluation of nephroprotective, diuretic, and antioxidant activities of *Plectranthus amboinicus* on acetaminophen-induced nephrotoxic rats. **Toxicol. Mech. Methods.** 20(4):213-221.



- Patel, R., K.M. Naveen, G. Ravindra, K. Basant, and K.S. Sudarshan. 2010a. Diuretic activity of leaves of *Plectranthus amboinicus* (Lour.) Spreng in male albino rats. **Phcog. Res.** 2(2):86-88.
- Patel, R., M. Naveen, W. Naheed, U. Nitin and S. Sudarshan. 2010b. Phyto-physicochemical investigation of leaves of *Plectranthus amboinicus* (Lour) spreng. **Phcog. J.** 2(13):536-542.
- Pavla, A. and A.D. Gurgel,. 2009. In vivo study of the anti-inflammatory and antitumor activities of leaves from *Plectranthus amboinicus* (Lour.) Spreng (Lamiaceae). **J. Ethnopharmacol.** 125:361-363.
- Pillai, P.G. P. Suresh, A. Gayatri, D. Gaurav, and B. Vidhi. 2011. Pharmacognostical standardization and toxicity profile of the methanolic leaf extract of *Plectranthus amboinicus* (Lour) Spreng. **J. App. Pharm. Sci.** 1(2):75-81.
- Rice, L.J. G.J. Brits, C.J. Potgieter, and J.V. Staden. 2011. *Plectranthus* : A plant for the future. **S. Afr. J. Bot.** 77(4):947-959.
- Roncal, C.A., M. Wei, C. Byron, R. Sirirat, O. Xiaosen, T.F. Isabelle, J.J. Richard, and A.A. Ejaz. 2007. Effect of elevated serum uric acid on cisplatin-induced acute renal failure. **AJP-Renal. Physiology.** 224(1):116-122.
- Sefi, M., H. Fetoui, N. Soudani, Y. Chtourou, M. Makni, and N. Zeghal. 2012. Pathology-research and practice *Artemisia campestris* leaf extract alleviates early diabetic nephropathy in rats by inhibiting protein oxidation and nitric oxide end products. **Pathol. Res. Pract.** 208(3):157-62.
- Shimada, M., R.J. Johnson, R.S. May, V. Lingegowda, P. Sood, T. Nakagawa, C.V. Quoc, B. Dass, and A.A. Ejaz. 2009. A novel role for uric acid in acute kidney injury associated with tumour lysis syndrome. **Nephrol. Dial. Transplant.** 24(7):2960-2964.
- Sindhu, R.K., E. Ashkan, F. Farbod, K.D. Kanwaljit, T. Nguyen, D.Z. Chang, K.R. Christian, and D.V. Nosratola. 2005. Expression of catalase and glutathione peroxidase in renal insufficiency. **BBA. Mol. Cell. Res.** 1743(1-2):86-92.
- So, A. and B. Thorens. 2010. Uric acid transport and disease. **J. Clin. Investig.** 120(6):1791-1799.
- Song, S., M. Meyer, T.R. Türk, B. Wilde, T. Feldkamp, and R. Assert. 2009. Serum cystatine C in mouse models: A reliable and precise marker for renal function and superior to serum creatinine. **Nephrol. Dial. Transplant.** 24(4):1157-1161.
- Soni, H. and K.S. Akhlesh. 2012. Recent updates on the genus *Coleus* : A review. **Asian. J. Pharm. Clin. Res.**5(1):12-17.
- Zhou, B., C. Tong, L. Cui, C. Li, Z. Fu, and L. Cui. 2014. IL-1 $\beta$  is related to hyperuricemic nephropathy induced by high-purine diet. **Gout and Hyperuricemia.**1(4):151-156.
- Zhou, Q., R.H. Xiao, J. Yu, X. Yu, and H.Y. Lan. 2015. Long noncoding RNA arid2-IR is a novel therapeutic target for renal inflammation. **Mol. Ther.** 23(6):1034-1043.