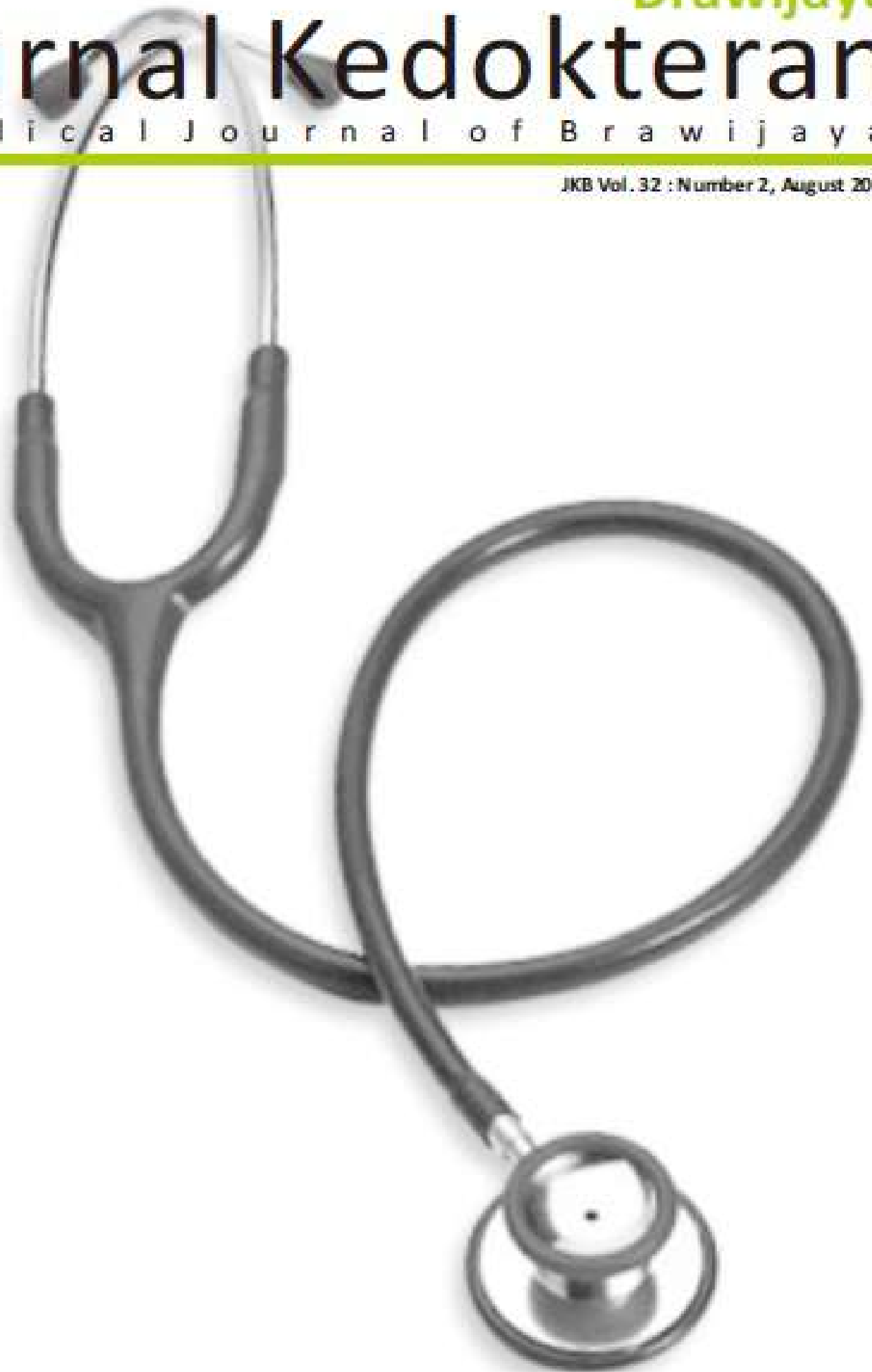

Brawijaya

Jurnal Kedokteran

M e d i c a l J o u r n a l o f B r a w i j a y a

JKB Vol. 32 : Number 2, August 2022





Editorial Team

Editor in Chief

Viera Wardhani, <https://scholar.google.co.id/citations?user=TkieHskAAAAJ&hl=id&oi=ao>, Faculty of Medicine Universitas Brawijaya, Indonesia

Editorial Board

Asti Melani Astari, <https://scholar.google.com/citations?user=ajXwW8EAAAAJ&hl=id>, Faculty of Medicine Universitas Brawijaya, Indonesia

Dewi Kartikawatiningsih, <https://scholar.google.co.id/citations?user=dK8uLgUAAAAJ&hl=en>, SintaID: 5994340, Faculty of Medicine Universitas Brawijaya. School of Social Welfare School of Public Health Graduate Certificate Program in Health Disparities, State University of New York, Albany-New York, United States

Desak Ketut Indrasari Utami, <https://scholar.google.co.id/citations?user=VfoGfpEAAAAJ&hl=id>, Neurology Departemen Medical Faculty of Udayana University, Indonesia

Dian Handayani, (ScopusID: 56035896000), Jurusan Gizi - Faculty of Medicine Universitas Brawijaya, Indonesia

Dian Nugrahenny, (ScopusID: 55907116600), Faculty of Medicine Universitas Brawijaya, Indonesia

Diana Lyrawati, (ScopusID: 6503907038), Faculty of Medicine Universitas Brawijaya, Indonesia

Holipah Holipah, <http://orcid.org/0000-0002-6143-8239>, Faculty of Medicine Universitas Brawijaya. Departement of Public Health, University of Miyazaki

Husnul Khotimah, <https://scholar.google.co.id/citations?user=2yxMSREAAAAJ&hl=id&oi=ao>, Faculty of Medicine Universitas Brawijaya, Indonesia

Ira Kusumawaty, <https://scholar.google.co.id/citations?user=HEPuAsUAAAAJ&hl=id>, Poltekkes Kemenkes Palembang, Indonesia

Loeki Enggar Fitri, (ScopusID: 36080235500), Faculty of Medicine Universitas Brawijaya, Indonesia

Syahrul Chilmi, https://scholar.google.com/citations?user=y_JfIK0AAAAJ&hl=en, Faculty of Medicine Universitas Brawijaya, Indonesia

Tri Siswati, <https://scholar.google.co.id/citations?user=1zc3ED0AAAAJ&hl=id>, Poltekkes Kemenkes Yogyakarta, Indonesia

Language Editor

Reza Nugraha, Founder of inFocus English, Malang, East Java, Indonesia

Peer Reviewers

Ahmad Dian Wahyudiono, <https://scholar.google.co.id/citations?user=D9Jw9BQAAAAJ&hl=id>, Faculty of Medicine Universitas Brawijaya, Indonesia

Ahsan Ahsan, <https://scholar.google.co.id/citations?user=DDQYBaQAAAAJ&hl=id&oi=ao>, Faculty of Medicine Universitas Brawijaya, Indonesia

Agustina Tri Endharti, (ScopusID: 6505560171), Faculty of Medicine Universitas Brawijaya, Indonesia

Aryo Dewanto, Post Graduate Program in Hospital Management, Faculty of Medicine Universitas Brawijaya, Indonesia

Basuki Bambang Purnomo, https://scholar.google.com/scholar?hl=id&as_sdt=0%2C5&q=basuki+purnomo&btnG=, Saiful Anwar Hospital, Indonesia

Besut Daryanto, <https://orcid.org/0000-0002-0776-1633>, Saiful Anwar Hospital, Indonesia

Cholid Tri Tjahjono, (ScopusID: 57192893732), Faculty of Medicine Universitas Brawijaya, Indonesia

Djoko Wahono S, <https://scholar.google.co.id/citations?user=VnIz2A4AAAAJ&hl=id>, Faculty of Medicine Universitas Brawijaya, Indonesia

Dearisa Surya Yudhantara, https://scholar.google.com/citations?user=N_IVxOAAAAJ&hl=id&authuser=1&oi=ao, Faculty of Medicine Universitas Brawijaya, Indonesia

Dewi Santosaningsih, <https://scholar.google.com/citations?user=3umANTUAAAAJ&hl=en>, Faculty of Medicine Universitas Brawijaya, Indonesia

Devita Rahmani Ratri, <https://scholar.google.com/citations?user=PpWVjcoAAAAJ&hl=en>, Faculty of Medicine Universitas Brawijaya, Indonesia

Edi Widjajanto, (ScopusID: 56006172100), Faculty of Medicine Universitas Brawijaya, Indonesia

Efta Triastuti, <https://scholar.google.co.id/citations?user=nv0bjBgAAAAJ&hl=en>, Faculty of Medicine Universitas Brawijaya, Indonesia

Ema Pristi Yunita, <https://scholar.google.co.id/citations?user=C1fT1GMAAAAJ&hl=id&oi=ao>, Faculty of Medicine Universitas Brawijaya, Indonesia

Eviana Norahmawati, <https://scholar.google.co.id/citations?user=MEcuBTYAAAAJ&hl=id>, Faculty of Medicine Universitas Brawijaya, Indonesia

Fajar Ari Nugroho, <https://scholar.google.co.id/citations?user=L7oACfIAAAAJ&hl=en>, Faculty of Medicine Universitas Brawijaya, Indonesia

Frilya Rachma Putri, <https://scholar.google.co.id/citations?user=J7DoBtIAAAAJ&hl=id>, Faculty of Medicine Universities Brawijaya, Indonesia

Harun Al Rasyid, <https://scholar.google.co.id/citations?user=EnP9WYAAAAAJ&hl=en>, Faculty of Medicine Universitas Brawijaya, Indonesia

Nikma Fitriasaki, <https://scholar.google.com/citations?user=HQBWIoAAAAAJ&hl=en>, Faculty of Medicine Universitas Brawijaya, Indonesia

Hidayat Suyuti, (ScopusID: 56231098000), Faculty of Medicine Universitas Brawijaya, Indonesia

Hikmawan Wahyu Sulistomo, <https://scholar.google.com/citations?user=uGoNILIAAAAJ&hl=en>, Faculty of Medicine Universitas Brawijaya, Indonesia

Inggita Kusumastuty, <https://scholar.google.co.id/citations?user=wEerbaUAAAAJ&hl=id>, Faculty of Medicine Universitas Brawijaya, Indonesia

I Wayan Arsana Wiyasa, https://scholar.google.co.id/citations?user=r_t92NgAAAAJ&hl=en, Faculty of Medicine Universitas Brawijaya

Krisni Subandijah, <https://scholar.google.co.id/citations?user=yQ-DdtwAAAAJ&hl=id>, Faculty of Medicine Universitas Brawijaya, Indonesia

Kurnia Widyaningrum, <https://scholar.google.co.id/citations?user=wHDeIAgAAAAJ&hl=en>, Faculty of Medicine Universitas Brawijaya, Indonesia

Lilik Zuhriyah, <https://scholar.google.com/citations?user=ZJNU2DUAAAAJ&hl=en>, Faculty of Medicine Universitas Brawijaya, Indonesia

Lukman Hakim, Faculty of Medicine Universitas Brawijaya, Indonesia

Muhammad Saifurrohman, (ScopusID: 8325126900), Faculty of Medicine Universitas Brawijaya, Indonesia

Muhammad Sasmito Djati, (ScopusID: 56403414400), Fakultas MIPA Universitas Brawijaya, Indonesia

Nadia Artha Dewi, <https://scholar.google.com/citations?user=CcARsGgAAAAJ&hl=en>, Faculty of Medicine Universitas Brawijaya, Indonesia

Noorhamdani AS, (ScopusID: 56639966500), Laboratorium Mikrobiologi Klinik, Faculty of Medicine Universitas Brawijaya, Indonesia

Novi Arfarita, https://scholar.google.co.id/citations?user=_ZCTEacAAAAJ&hl=id, Universitas Islam Malang & IRC-MEDMIND, Universitas Brawijaya, Indonesia

Novi Khila, <https://www.scopus.com/authid/detail.uri?authorId=57188973746>,
<https://scholar.google.co.id/citations?user=7FwnZqkAAAAJ&hl=id>, Faculty of Dentistry Universitas Brawijaya, Indonesia

Nur Samsu, <https://scholar.google.co.id/citations?user=mIbOS3MAAAAJ&hl=en>, Faculty of Medicine Universitas Brawijaya, Indonesia

Putu Eka Sudaryatma, https://www.researchgate.net/profile/Putu_Sudaryatma, Balai Karantina Ikan, Pengendalian Mutu dan Keamanan Hasil Perikanan Denpasar Bali, Veterinary Microbiology, Miyazaki University Japan, Indonesia

Retty Ratnawati, <https://scholar.google.com/citations?user=ZoVj1nEAAAAJ&hl=en>, Department of Physiology Faculty of Medicine Universitas Brawijaya, Indonesia

Respati Suryanto Dradjat, <https://scholar.google.co.id/citations?user=P-Cvbh0AAAAJ&hl=en>, Faculty of Medicine Universitas Brawijaya, Indonesia

Sanarto Santoso, (ScopusID: 56118471300), Faculty of Medicine Universitas Brawijaya, Indonesia

Susanthy Djajalaksana, <https://scholar.google.co.id/citations?user=jm3t94AAAAJ&hl=en>, Faculty of Medicine Universitas Brawijaya, Indonesia

Saptadi Yulianto, <https://scholar.google.co.id/citations?user=X6t23HIAAAAJ&hl=id>, Faculty of Medicine Universitas Brawijaya, Indonesia

Septi Dewi Rachmawati, <https://scholar.google.co.id/citations?user=PrKyPTAAAAJ&hl=en>, Faculty of Medicine Universitas Brawijaya

Seskoati Prayitnaningsih, <https://scholar.google.co.id/citations?user=mMASaz8AAAAJ&hl=en>, Faculty of Medicine Universitas Brawijaya, Indonesia

Setyawati Soeharto Karyono, (ScopusID: 56367333100), Faculty of Medicine Universitas Brawijaya, Indonesia

Shahdevi Nandar Kurniawan, <https://scholar.google.ca/citations?user=CwTE1i4AAAAJ&hl=en>, Faculty of Medicine Universitas Brawijaya, Indonesia

Sri Sunarti, (ScopusID: 56483311200), Faculty of Medicine Universitas Brawijaya, Indonesia

Sutiman Bambang Sumitro, (ScopusID: 55218596400), Fakultas MIPA Universitas Brawijaya, Indonesia

Taufiq Nur Budaya, <https://scholar.google.co.id/citations?user=iVUt3ZAAAAAJ&hl=en>, Faculty of Medicine Universitas Brawijaya, Indonesia

Teguh Wahyu Sardjono, (ScopusID: 57192300853), Faculty of Medicine Universitas Brawijaya, Indonesia

Tita Hariyanti, <https://scholar.google.co.id/citations?user=oDMAJTsAAAAJ&hl=id&oi=ao>, Faculty of Medicine Universitas Brawijaya, Indonesia

Valentina Yurina, (ScopusID: 56176863500), Faculty of Medicine Universitas Brawijaya, Indonesia

Widodo Widodo, (ScopusID: 57190247745), Fakultas MIPA Universitas Brawijaya, Indonesia

Wisnu Barlianto, (ScopusID: 56639963100), Faculty of Medicine Universitas Brawijaya, Indonesia

Yuyun Yueniwati, <https://scholar.google.co.id/citations?user=Cox9BfMAAAAAJ&hl=id>, Radiology Department, Faculty of Medicine, Universitas Brawijaya, Malang, Indonesia

Assistant Editor

Dini Suryaning Mentari, Fakultas Kedokteran Universitas Brawijaya, Indonesia

About JKB

[Aim and Scope](#)

[Publication Ethics](#)

[Visitor Statistic](#)

[Contact Us](#)

Information for Author

[General Information](#)

[Online Submissions](#)

[Author Guidelines](#)

[The Authors Data](#)

[Ethics Statement](#)

[Template](#)

Information for Reviewer

[Peer Review Process](#)

[Make a Submission](#)

TEMPLATES

[Template
Research Article](#)

[Template
Case Report](#)

[Author Data](#)

[Ethics Statement](#)

Index





Metadata from
Crossref

Google Scholar



GARUDA
GARBA RUJUKAN DIGITAL

Tools



Mendeley



grammarly



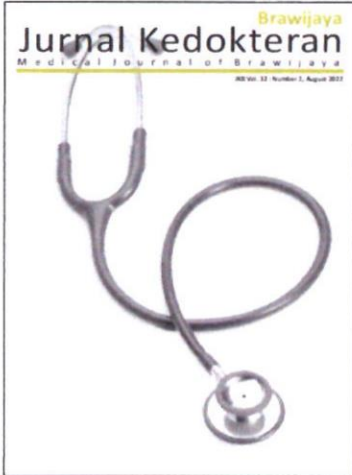
turnitin™

Tools

[Mendeley User Guide](#)



Vol. 32 No. 2 (2022)



Published: 2022-08-31

Research Article

[Effect of Simvastatin on Eosinophilic Inflammation of Bladder Tissue in Interstitial Cystitis Rat Model](#)

Muhamad Nur Syukriani Yusuf, Abdi Dzul Ikram Hasanuddin, Zuhriana K Yusuf, Trinny Tuna, Nurani Ibrahim, Marshanda Tiara Posumah, Ridho Tianggara

p.76-81



PDF

[Effect of Simvastatin Administration on ALP \(Alkaline Phosphatase\) Level in Wistar Rat's Femur Fracture](#)

Hery Susilo, Edi Mustamsir, Wanda Gusta Rai

p.82-86



PDF

[Antioxidant Properties of TeNan Herbal Tea Formulation "Telang \(Clitoria ternatea\) and Pineapple \(Ananas comosus\)"](#)

Wahyu Widowati, Teresa Liliana Wargasetia, Meganita Marthania, Tazkia Salma Hanifa, Teddy Marcus Zakaria, Michael Sebastian Gunadi, Natanael Halim, Sheryl Santiadi

p.87-93



PDF

Comparative Assessment of the Safety between Pazopanib and Sunitinib for Metastatic Renal Cell Carcinoma

Eka Yudha Rahman, Choirin Nur, Deddy Rasyidan Yulizar

p.94-103



Chromosome Aberration on Growth and Developmental Disorder

Eva Diah Setijowati, Herni Suprpti, Maria Widijanti Sugeng, Retno Dwi Wulandari

p.104-110



Predictor Factor for Severity Degree of Pediatric Hydronephrosis in Tertiary Hospital

Hamdan Yuwafi Naim, Besut Daryanto, Pradana Nurhadi

p.111-115



Demographic, Clinical, and Laboratory Characteristics of HIV Patients with Cerebral Toxoplasmosis at Haji Adam Malik General Hospital Medan

Alfansuri Kadri, Eko Yandra

p.116-119



Perceived Family Functionality among Elderly Patient with Covid-19 Infection: A Perspective from Developing Country

Sri Sunarti, Didi Candradikusuma, Dewi Indiestari, Siti Fatma Prehatiningsih, Bogi Pratomo Wibowo, Affa Kiysa Waafi

p.120-126



Case Report

46 XX Congenital Adrenal Hyperplasia (CAH) after Clitoroplasty, Labioplasty, and Vaginoplasty

Rahmat Husein, Besut Daryanto, Paksi Satyagraha, Pradana Nurhadi

p.127-132



A Two-Year-Old Boy with Diphallia and Multiple Congenital Anomalies

Rizal Trianto, Pradana Nurhadi, Besut Daryanto

p.133-137



Research Article

Chromosome Aberration on Growth and Developmental Disorder

Abnormalitas Kromosom pada Gangguan Tumbuh Kembang

Eva Diah Setijowati¹, HERNI SUPRPTI², MARIA WIDIJANTI SUGENG³, RETNO DWI WULANDARI⁴

^{1,4}Department of Biomedical Science Laboratory of Medical Genetics Faculty of Medicine Universitas Wijaya Kusuma Surabaya

²Department of Pharmacology Faculty of Medicine Universitas Wijaya Kusuma Surabaya

³Department of Pathology Anatomy Faculty of Medicine Universitas Wijaya Kusuma Surabaya

ABSTRACT

Growth and development in humans begin at conception, which shows progress and interdependence. Normal children show the characteristic of growth and development. In children with growth and development disorder, chromosomal abnormality may be found. This study aimed to determine chromosomal abnormality in patients with growth and development disorder. The samples were taken from karyotype results of patients in the Medical Genetics Laboratory, Faculty of Medicine, Universitas Wijaya Kusuma Surabaya, from 2010-2020. The inclusion criteria were infants to adolescents aged 24 years and unmarried who experienced impaired growth and development, including sexual development. Chromosomal abnormalities were obtained from cytogenetic analysis using the G-banding method. From 75 samples with growth and development disorders, there were abnormalities in the number of autosomal chromosomes and sex chromosomes found in patients with Down syndrome, Turner syndrome, Klinefelter syndrome, and Edwards syndrome. Chromosomal structural abnormalities found were deletion, translocation, inversion, duplication, marker chromosome, and heteromorphism. This study showed the importance of karyotyping in children and adolescents with growth and developmental disorders.

Keywords: Chromosomes, development, disorders, growth

ABSTRAK

Pertumbuhan dan perkembangan pada manusia dimulai sejak konsepsi dan menunjukkan kemajuan serta saling ketergantungan. Karakteristik pertumbuhan dan perkembangan dapat diamati pada anak-anak normal. Pada anak-anak dengan gangguan pertumbuhan dan perkembangan dapat ditemukan adanya kelainan kromosom. Penelitian ini bertujuan untuk mengetahui abnormalitas kromosom pada pasien dengan gangguan tumbuh kembang. Sampel berasal dari hasil karyotiping pasien di laboratorium Genetika Medik Fakultas Kedokteran Universitas Wijaya Kusuma Surabaya tahun 2010-2020. Kriteria inklusi adalah bayi sejak dalam kandungan hingga remaja berusia 24 tahun dan belum menikah yang mengalami gangguan pertumbuhan dan perkembangan, termasuk perkembangan seks. Abnormalitas kromosom didapat dari analisis sitogenetika dengan metode *G-banding*. Dari 75 sampel dengan gangguan pertumbuhan dan perkembangan didapatkan kelainan jumlah kromosom otosom atau kromosom seks, yaitu pada pasien-pasien dengan sindroma Down, sindroma Turner, sindroma Klinefelter dan sindroma Edward. Kelainan struktur kromosom yang ditemukan adalah delesi, translokasi, inversi, duplikasi, kromosom marker dan heteromorfisme. Hasil penelitian menunjukkan pentingnya anak-anak hingga remaja dengan gangguan tumbuh kembang untuk menjalani pemeriksaan kromosom.

Kata Kunci: Gangguan, kromosom, perkembangan, pertumbuhan

Correspondence: Retno Dwi Wulandari. Department of Biomedical Science, Laboratory of Medical Genetics, Faculty of Medicine, Universitas Wijaya Kusuma Surabaya Tel. 081231498858 Email: retno.wulandari@uwks.ac.id

DOI: <http://dx.doi.org/10.21776/ub.jkb.2022.032.02.5>

INTRODUCTION

All life forms show growth and development that start at conception and end when they reach maturity. The terms growth and development are used together. In normal children, growth and development are progressing and interdependent. Growth is defined as the increase of length or height, body mass, or other measurements due to the number of cells that leads to an overall increase. These increases can be seen, valued, and accurately measured (1,2).

Growth and development are unique characteristics of children, and any inhibition at any stage of these processes can lead to growth and development impairment. Besides a 10% prevalence of developmental delay, it is important to emphasize that identifying growth and development disorders are still difficult. Although severe disorders can be recognized at infancy, diagnosing speech difficulty, hyperactivity, or emotional disturbance before 3-4 years old is not easy, and learning disorders are rarely recognized before they enter school (1).

Child development includes sexual development that is not only about sex but includes values, feelings, attitudes, interactions, and behaviors. Sexual development is a part of sexuality, and it begins earlier in life than puberty (3). Disorders of sex development (DSDs) are congenital disorders in which gonad and phenotype do not match the individual's karyotype. The term DSDs covers a broad clinical spectrum that can be diagnosed at any age range, from the neonatal until adulthood, which are due to infertility problems. The clinical conditions vary from external genitalia ambiguity recognized at birth to mild forms, such as mild hypospadias or unilateral cryptorchidism, postnatal virilization, delayed/absent puberty, or infertility (4,5). The development of sex-specific gonad starts with the formation of bipotential gonad, which then differentiates to either testicular or ovarium tissue (4).

Congenital abnormalities in DSDs include abnormalities in chromosomes (numerical or structural), genes involved in gonadal and/or genital development, and changes in gonadal and/or adrenal steroidogenesis (6). Therefore, the etiological diagnosis of DSDs generally requires endocrinological tests, radiological images, and genetic tests. Generally, the initial test is the chromosome examination for classifying the abnormalities (4). Disorders of sex development related to the atypical arrangement of sex chromosomes are the Turner syndrome and its variants, the Klinefelter syndrome and its variants, and mosaicism in sex chromosome (45,X/46,XY or 46,XX/46,XY) (7-9).

As growth and sexual development disorders might be caused by chromosome aberration, this study used data from chromosome analysis on children with growth disorder and sexual developmental disorder during 2010-2021 at the Medical Genetics laboratory, Medical Faculty, Universitas Wijaya Kusuma Surabaya.

METHODS

Patients

This study involved 75 subjects who met the inclusion criteria that were children and adolescents with growth and/or developmental disorder, including sexual development disorder. Based on the Law of the Republic of Indonesia Number 23 Year 2002 article 1 paragraph 1 concerning child protection, a child is someone who has not reached the age of 18 (eighteen), including a fetus in the womb. According to the Regulation of the Minister of Health of the Republic of Indonesia number 25 Year 2014, an adolescent is someone from 10-18 years old; and, according to the National Population and Family Planning Agency (BKKBN), an adolescent is someone in the age range of 10-24 years and not married yet. Therefore, in this study, children and adolescents were from babies in the womb to the age of 24 years and were not married. All

Table 1. Phenotype of growth and developmental disorder, syndrome, and karyotype

The Phenotype of Growth and Developmental Disorder	Syndrome	Type	Karyotype	Total 63 n (%)
Short stature ¹⁾ , underweight and developmental delay	Down syndrome	Pure Trisomy 21	47,XX/XY,+21	39 (61.9)
		with structural aberration	47,XX,+21,dup(16)(q11.2) 47,XY,+21,inv(9)(p21;q21) 47,XY,+21,9q12h+	
Multiple congenital anomaly (not specified)		Pure Trisomy 18	47,XX,+18	2(3.2)
<i>Atrial septal defect (ASD)</i> , multiple congenital disorder: <i>Patent Ductus Arteriosus (PDA)</i> , <i>Dextro Cardia</i> , polydactyly	Edward syndrome	with structural aberration	46,XX,t(13;13),+13(37%)/46,XX,t(13;der13),+13(63%)	1(1.6)
Sexual developmental disorder: undescensus testis, no axilla hair	Klinefelter syndrome	pure	47, XXY	3 (4.8)
Short stature, primary amenorrhea		mosaicism	47,XXY/46,XY	1(1.6%)
Three samples with female phenotype, primary amenorrhea, and lack of secondary sexual development; One sample with male phenotype and undescensus testis		pure	45,X	6 (9.5)
Female phenotype with short stature (25-50 th percentile), primary amenorrhea, weight, and height (31 kg/134 cm)	Turner syndrome and its variation		45,X(12,5%)/46,X,del(X)(qter-->p11.2)(87.5%)	7(11)
A three-month-old male with sex ambiguity and <i>scrotum bifidum</i> .		Chromosome number	45,X(30%)/46,X,+mar(70%)	
An 18 yo female, short stature (<5 th percentile) with weight and height (29 kg/126 cm)		mosaicism with structural aberration	45,X(39.48%)/47,X,+2mar1(60.52%)	

Note: ¹⁾Based on the Down syndrome growth chart(11), ²⁾Based on the Turner syndrome growth chart(12)

Table 2. Phenotype of growth and developmental disorder, structural aberration, and chromosomal analysis result

Growth and Developmental Disorder	Chromosome Structure Aberration	Karyotype	Total 20 n(%)
A 16 yo female with primary amenorrhea, underdeveloped breast, lack of axilla and pubic hair, no uterus and short stature (<5 th percentile) ²⁾	Translocation	46,XX,t(3;18)(q13.2;p11.1)	1(5)
A 22 yo female with with short stature (<5 th percentile) ²⁾		46,XX,t(3;18)(q13.2;p11.1)	1(5)
A 19-day female baby with Multiple Congenital Anomaly: ASD, PDA, Dextro Cardia, polydactyly		46,XX,t(13;13),+13(37%)/46,XX,t(13;der13),+13(63%)	1(5)
A 14 yo female with Primary amenorrhea, lack of secondary sexual development, short stature		46,X,del(Xp)	1(5)
A 9 yo male with bilateral undescended testicles, hypospadias	Deletion	46,XY,del(Yq)	1(5)
A 15 yo female with primary amenorrhea, lack of secondary sexual development, short stature		46,X,del(X)(q22-->qter)	1(5)
A 15 yo female with primary amenorrhea, short stature ¹⁾ lack/scarce of axilla and pubic hair, no ovarium		45,X(12,5%)/46,X,del(X)(qter-->p11.2)(87.5%)	1(5)
An 18 yo female with short stature (<5 th percentile) ¹⁾ (susp. Turner syndrome)	Marker	45,X(39.48%)/47,X,+2mar1(60.52%)	1(5)
A 3 Ambiguous genitalia, scrotum bifidum, testes +/-, macropenis	chromosome (mosaicism)	45,X(30%)/46,X,+mar(70%)	1(5)
A 10 th female, born without crying, developmental delay, speech delay, hearing disorder, short stature (height <5 th percentile) ²⁾ , thin	Inversion	46,XX,inv(9)(p12q13)	1(5)
An 11 yo male with intellectual disability		46,XY,inv(9)(p11;q23)	1(5)
A 9 yo male with developmental delay		47,XY,+21,inv(9)(p21;q21)	1(5)
An 18 yo female with primary amenorrhea		46,XY,var(9)dup(9)(q12)	1(5)
A 1.5 yo female with developmental delay		47,XX,+21,dup(16)(q11.2)	1(5)
Sexual developmental disorder: penoscrotal hypospadias, scrotum bifidum	Duplication	46,XY,dup(9)(q12;q13)	2(10)
Sexual developmental disorder: subcoronal hypospadias, undescensus left and right testicles		46,XY,dup(18)(q23)	1(5)
Down syndrome phenotype: hypertelorism, flat nose, protruding tongue		46,XY,dup(9)(q12;q13)	1(5)
Down syndrome phenotype; cataract	Heteromorphism	47,XY,+21,9q12h+	2 (10)

Note:

ASD=atrial septal defect

PDA=Patent ductus arteriosus

¹⁾Based on the Turner syndrome growth chart (12)²⁾Based on the CDC Growth chart (13)

patients with growth and/or development disorders were grouped according to phenotype, chromosomal features, or karyotype, including chromosomal abnormalities, chromosomal structural abnormalities, and the syndrome suffered.

Cell Culture Method

Chromosome analysis was done using G-banding analysis (400 bands) (10). As much as 3 ml of peripheral venous blood was inserted into a venoject containing sodium heparin. A total of 0.4 ml of blood was then put into a Nunc tube or 15 ml tube containing culture media and incubated in a 5% CO₂ incubator for 72 hours. On the 3rd day before harvesting, colcemid was added to the culture media to stop the mitosis at metaphase. After centrifugation at 3500 rpm for 10 minutes and supernatant aspiration, hypotonic solution was then given to swell and lyse the cells. Fixatif solution (methanol:acetic acid=3:1) was added, followed by centrifugation and supernatant aspiration. This process was carried out repeatedly until clear solution was obtained, then the pellet at the bottom of the tube was dripped on an object glass and dried before staining using Giemsa.

G-banding Analysis

After staining with Giemsa, the chromosomes could be seen under a microscope at 1500 times magnification aided with immersion oil. The total number of cells counted was 30-50 for each sample.

RESULT

A total of 75 samples were grouped based on the type of growth and development disorder (phenotype), the syndromes, and the karyotype (Table 1). The samples were grouped based on the type of growth and development disorder and the phenotype, as well as the chromosome structure aberration (Table 2).

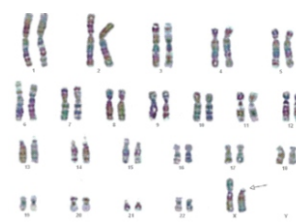


Figure 1. A 14 yo female with primary amenorrhea, lack of secondary sexual development, and short stature showing a deletion on Xp: 46,X,del(Xp)

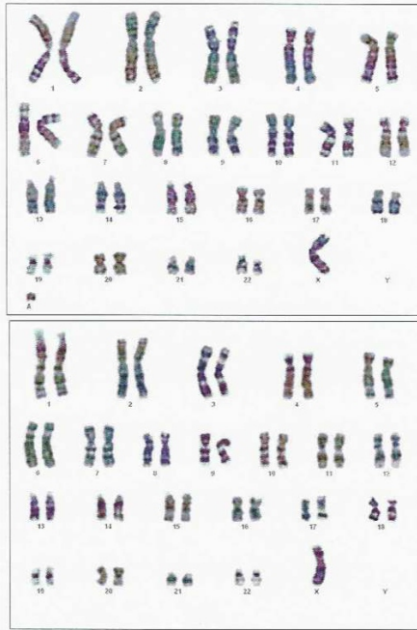


Figure 2. A 3 months baby with ambiguous genitalia, scrotum bifidum, testes +/+, macropenis showing mosaicism (normal karyotype and karyotype with a marker chromosome):
45,X(30%)/46,X,+mar(70%)

DISCUSSION

Patients with growth and/or developmental delay, including sexual developmental delay, in this study, showed (either or both) numerical or structural chromosome aberration (translocation, deletion, inversion, duplication, and marker chromosome) as well as sex chromosome aneuploidy. Mosaicism (two or more groups of cells with different karyotypes in one individual) was found in 9 patients, 4 of them showed 45,X/46,XY mosaicism with phenotype either female or male.

Down syndrome or trisomy 21 was the most growth and developmental disorder found in this study. With the live birth incidence at approximately 1:800, Down syndrome was the most common cause of genetic cause of intellectual disability. Babies with Down Syndrome experience hypotonia or muscle weakness, resulting in delays in development, such as the ability to prone, sit, and walk. The delay also occurs in the ability to speak (14). Patients with Down syndrome show characteristic phenotypes that are upslanting palpebral fissure, flat nasal bridge, epicanthal folds, hypertelorism, flat occiput, simian crease, and strabismus (15).

Individuals with Down syndrome also show growth and sexual development delay. With an adult height of approximately 150 cm, they seem shorter than their peers. In this study, Down syndrome height was measured using a Down syndrome growth chart (11). Children with Down syndrome also experience a sexual developmental delay. Male with Down syndrome will become fully sexually mature but later than normal individuals (16). While in the females, their menarcheal age does not differ from the general population (17,18).

Aneuploidy in sex chromosomes found in this study were Turner (and its variation) and Klinefelter syndromes. Females with Turner syndrome also suffer from growth and developmental disorder. Their main characteristics

are short stature (>90%) seen at birth, during childhood, and final height below the average female height in the specific population. The cause of short stature is not fully understood but may be caused by SHOX gene haploinsufficiency (on the Pseudoautosomal region/PAR) (18,19) rather than primary disorder in the GH-IGF axis or the absence of sex steroids. Patients with Turner syndrome also experience no secondary sexual development (no breast development and axilla and pubic hair) and ovarian failure that causes primary amenorrhea and infertility (19).

Percentage rather than half Turner syndrome individuals have 45,X karyotype. Some show variations, which in this study were in the form of mosaic: 46,X del(Xp), del(X)(qter-->p11.2) and del(X)(q22-->qter). Females with partial monosomy on the X chromosome show variation of their phenotype. Patients with Xp deletion present with short stature, which is around 2% among Turner syndrome patients. Genes on the short arm of the X chromosome (in PAR) in normal females (46,XX) do not experience X inactivation; therefore, one or more genes deletion in PAR can cause clinical implications. Since the ovarian function remains normal, terminal Xp deletion can be passed to the next generation (20). There were no examinations on the patient's mother in this study, so it was unknown whether partial Xp deletion in this patient was inherited.

In this study, there were 4 patients with mosaic Turner syndrome (45,X/46,XY). These sex chromosome differences are thought to occur in mitosis after fertilization of an embryo with a 46,XY karyotype. In the subsequent cell division, the Y chromosome became lost due to non-disjunction (postzygotic mitotic error), so that there are cells that lose their Y chromosome (45,X) (21). Individuals with a 45,X/46,XY karyotype exhibit varying phenotypes, ranging from a seemingly normal appearance to showing clinical signs of Turner syndrome with incomplete sexual differentiation. In general, 60% of cases with a 45,X/46,XY karyotype exhibit ambiguous genitalia (21). There were 4 patients with 45,X/46,XY karyotype: 3 patients had female phenotype, and the remaining had male phenotype. In patients with female phenotype, sexual developmental disorders experienced were lack of secondary sex development and primary amenorrhea (patient 1), ambiguous sex (clitoral enlargement) (in patient 2), and short stature and no secondary sex development (patient 3). In patients with a male phenotype, the developmental disorder found was undescended testis.

Another mosaicism was found in a patient with 45,X(39.48%)/47,X,+2mar1(60.52%) and 45,X(30%)/46,X,+mar(70%) karyotype. The fertilization zygote may have 47,X with the addition of 2 marker chromosomes (abbreviated as mar by ISCN, 2013). Marker chromosome is an additional chromosome that is small, abnormal in structure, and without banding pattern (22). Non-disjunction that occurs in a mitotic event in an embryo causes the loss of marker chromosome due to the abnormal structure so that the result of mitosis is a daughter cell with a 45,X karyotype. The other cells that do not undergo mitotic non-disjunction retain the initial karyotype resulting from fertilization. Patients with karyotype 45,X(39.48%)/47,X,+2mar1(60.52%) showed female karyotype, short (height <5th percentile) as in CDC, 2000(13), but further molecular examination showed the presence of SRY gene; another patient with 45,X(30%)/46,X,+mar(70%) karyotype was a baby boy ascertained with

scrotum bifidum (with palpable testicles) and micropenis. Other mosaicism was 45,X(12,5%)/46,X,del(X)(qter-->p11.2)(87.5%) in 15 yo female. The possible fertilization result was 46,X,del(X)(qter-->p11.2) zygote, but after subsequent mitotic events, non-disjunction occurred, so that there were daughter cells that lost their X qter-->p11.2 deletion chromosome as deletion chromosome was structurally abnormal, while other cells that do not undergo non-disjunction retain the original karyotype as fertilized.

The other sex chromosome aneuploidy was Klinefelter syndrome. The incidence ranges between 1:581 and 1:917 of live male birth. However, only 25% of this population will be diagnosed in childhood or later in adulthood after they experience developmental delay, behavioral disruptions, hypogonadism, gynecomastia, or infertility. During the infancy and pre-school period, individuals with Klinefelter syndrome experience growth and developmental disorder that includes hormonal, motor, speech, and behavioral development. In the transition to school age, impairment occurs in language difficulty, disfunction in execution, behavior, and reading and learning deficits (23).

Males with Klinefelter syndrome show characteristic symptoms such as typical physical and neurodevelopmental manifestation focused on growth, cognitive development, endocrine function, and reproduction. Based on a study, the optimum result depends on early detection combined with long-life consistent and targeted treatment on neurodevelopmental (23). In this study, Klinefelter syndrome was accompanied by sexual developmental delay, and one patient showed hypospadias. There were no data about his cognitive ability. In this study, the number of Klinefelter syndrome was smaller than Turner syndrome since many males with Klinefelter syndrome may be undiagnosed due to the unspecific symptoms, variation in clinical presentation, and no dysmorphic appearance. Postnatal diagnosis is usually made due to physical abnormality in early childhood, such as hypospadias, small phallus, or cryptorchidism (23).

The abnormalities in chromosome structure found in this study were translocation, duplication, deletion, inversion, marker chromosome and heteromorphism. Duplication in the chromosome segment will double the DNA sequence and gene dosage on this segment, influencing the phenotype. In this study, two patients with karyotype 46,XY,dup(9)(q12;q13) showed sexual developmental disorder: hypospadias, scrotum bifidum, and microtestis. In contrast, another patient with the same karyotype showed hypertelorism, flat nose, and protruding tongue, similar to Down syndrome phenotype. The other duplication was found in a patient with 47,XX,+21,dup(16)(q11.2) karyotype. Since the patient had trisomy 21, the patient showed a Down syndrome phenotype with growth and developmental disorder.

In this study, a patient with Karyotype 46,XY,dup(18)(q23) showed hypospadias, bilateral undescensus testis, and intellectual disability. Patient with trisomy 18 (Edwards syndrome) is purely intellectually disabled as well as other congenital abnormalities. Meanwhile, some patients with partial trisomy 18 are known to show variation in severity from relatively mild without any internal organ malformation to a classical characteristic of Edwards syndrome. Some researchers have tried to identify which

region on chromosome 18 is the critical region (CR) for Edwards syndrome. Partial duplication of chromosome 18q, which involves the CR was reported in patients with Edwards syndrome phenotype. The literature stated that partial duplication of proximal chromosome 18q would be more severe than if the duplication occurs in the distal part (24).

Another chromosome structure abnormality in this study was the deletion or missing of segment chromosome, which means loss of genes on the deleted segment. This study found patients with Xp chromosome deletion, that are 2 patients with Xq deletion and 1 with Yq deletion. Patients with X or Y partial deletion showed sexual developmental disorder, namely primary amenorrhea (partial X del), undescensus testes, and hypospadias (del Yq). All female patient with del X has short stature, even in mosaic monosomy X.

This study also found inversion or chromosome segment which is reversed in position. Of all patients with an inversion, all of them involved an inversion of the centromere of chromosome 9 (pericentric inversion). All patients were accompanied by mental retardation and developmental delay. One patient showed mosaicism: inversion and trisomy 21; therefore, the patient showed Down syndrome phenotype.

Translocation or segment chromosome transfer between non-homolog chromosomes was found in five patients. Transfer happens between non-acrocentric chromosomes (reciprocal translocation) and between acrocentric chromosomes (Robertsonian translocation). Reciprocal translocation is more common, and a translocation carrier usually does not show any abnormalities, but their offspring may exhibit abnormal phenotype or karyotype due to the addition of genetic material (25). There were two patients with reciprocal chromosomes between chromosome 3 and 18 who showed short stature and one patient with translocation between chromosome 13 and 13 showed multiple congenital anomalies. No patient with Robertsonian translocation.

In this study, a patient was found with Heteromorphism, a normal variant that can be detected using G-banding. Chromosome 9 showed the most morphology variant among non-acrocentric chromosomes in humans. These variants, such as 9qh+, 9cenh+, 9ph+, 9qh- or inv(9)(p11q13), are commonly detected in routine karyotyping, and the estimated frequency is 1.5% in the general population (26). The patient with heteromorphism (9q12h+) in this study also had trisomy 21, so the patient showed Down's syndrome phenotype.

Chromosome aberrations, either numerical or structural, are known to cause growth and developmental disorder, developmental delay, including sexual developmental disorder. This study showed that patients with growth and developmental disorders had numerical aberration (autosome and sex chromosomes) or chromosome structure aberration (translocation, deletion, inversion, duplication, heteromorphism, and marker chromosome).

ACKNOWLEDGMENTS

This work was supported by grant (No.105/LPPM/UWKS/VIII/2020) from LPPM Fakultas Kedokteran Universitas Wijaya Kusuma Surabaya.

The authors would like to thank dr. Pratika Yuhyi H, MSc., PhD. and Luluk Tursilowati, AMd., SPd for laboratory's work assistance.

ABBREVIATION LIST

ASD	: <i>atrial septal defect</i>
BKKBN	: Badan Kependudukan dan Keluarga Berencana Nasional
CR	: <i>Critical Region</i>
DSD	: <i>Disorders of Sexual Development</i>
PDA	: <i>Patent Ductus Arteriosus</i>

REFERENCES

- Arun R, Shailaja, and Rao Prasanna. *Growth and Development in Children: An Ayurvedic Perspective*. International Journal of Ayurvedic and Herbal Medicine. 2013; 3(5): 1337–1342.
- Koletzko B, Chourdakis M, Grote V, et al. *Regulation Of Early Human Growth: Impact on Long-Term Health*. Annals of Nutrition & Metabolism. 2014; 65(2-3): 101–109.
- National Sexual Violence Research Center. *An Overview on Healthy Childhood Sexual Development*. (Online) 2016. <https://www.nationalcac.org/wp-content/uploads/2016/08/HealthySexualDevelopmentOverview.pdf>
- García-Acero M, Moreno-Niño O, Suárez-Obando F, et al. *Disorders of Sex Development: Genetic Characterization of a Patient Cohort*. Molecular Medicine Reports. 2020; 21(1): 97–106.
- Witchel SF. *Disorders of Sex Development*. Best Practice & Research. Clinical Obstetrics & Gynaecology. 2018; 48: 90-102.
- Markosyan R. *Patients with Disorders of Sex Development*. Annals of Pediatric Endocrinology & Metabolism. 2021; 26(2): 74–79.
- Pang KC, Feldman D, Oertel R, and Telfer M. *Molecular Karyotyping in Children and Adolescents with Gender Dysphoria*. Transgender Health. 2018; 3(1): 147–153.
- Kohva E, Miettinen PJ, Taskinen S, Hero M, Tarkkanen A, Raivio T. *Disorders of Sex Development: Timing of Diagnosis and Management in a Single Large Tertiary Center*. Endocrine Connections. 2018; 7(4): 595–603.
- Vora KA and Srinivasan S. *A Guide to Differences/Disorders of Sex Development/Intersex in Children and Adolescents*. Australian Journal of General Practice. 2020; 49(7): 417–422.
- Howe B, Umrigar A, and Tsien F. *Chromosome Preparation from Cultured Cells*. Journal of Visualized Experiments: JoVE. 2014; (83): 3–7.
- Centers for Disease Control and Prevention. *Growth Charts for Children with Down Syndrome*. (Online) 2011. <https://www.cdc.gov/ncbddd/birthdefects/downsyndrome/growth-charts.html>
- Rieser P and Davenport M. *Turner Syndrome A Guide for Families. States, Turn Syndr Soc United States*. (Online) 2017. <https://turnersyndrome.foundation.org/wp-content/uploads/2017/08/New-Turner-Syndrome-Guide-for-Families-Patricia-Reiser-CFNP-and-Marsha-Davenport-MD.pdf>
- Centers for Disease Control and Prevention. *Growth Charts for Girls 2 to 20 years*. (Online) 2000. <https://www.cdc.gov/growthcharts/data/set1clinic>
- Turnpenny P and Ellard S. *Emery's Elements of Medical Genetics*. 15th edition. Amsterdam: Elsevier; 2017.
- Karkera S. *A Current Knowledge of "Down Syndrome: A Review."* Journal of Dental and Medical Sciences. 2021; 3(1): 805–810.
- Attia AM, Ghanayem NM, and El Naqeeb HH. *Sexual and Reproductive Functions in Men with Down'S Syndrome*. Menoufia Medical Journal. 2015; 28(2): 471-476.
- Nurkhairulnisa AI, Chew KT, Zainudin AA, et al. *Management of Menstrual Disorder in Adolescent Girls with Intellectual Disabilities: A Blessing or a Curse?* Obstetric and Gynecology International. 2018; 2018: 1-5.
- Oulmane Z, Hilali MK, Cherkaoui M. *Characteristics of Menarcheal Age, Menstrual Hygiene and Socio-Demographic Factors in Girls with Down Syndrome in Morocco*. Social Work in Public Health. 2021; 36(5): 537–547.
- Oktay K, Bedoschi G, Berkowitz K, et al. *Fertility Preservation in Women with Turner Syndrome: A Comprehensive Review and Practical Guidelines*. Journal of Pediatric and Adolescent Gynecology. 2016; 29(5): 409–416.
- D'Ambrosio F, Chan JT, Aslam H, Aguirre Castaneda R, De Simone L, and Shad Z. *Turner Syndrome Due to Xp22.33 Deletion with Preserved Gonadal Function: Case Report*. Oxford Medical Case Reports. 2019; 2019(5): 191–194.
- Efthymiadou A, Stefanou EG, and Chrysis D. *45,X/46,XY Mosaicism: A Cause of Short Stature in Males*. Hormones. 2012; 11(4): 501–504.
- Jafari-Ghahfarokhi H, Moradi-Chaleshtori M, Liehr T, Hashemzadeh-Chaleshtori M, Teimori H, and Ghasemi-Dehkordi P. *Small Supernumerary Marker Chromosomes and Their Correlation with Specific Syndromes*. Advanced Biomedical Research. 2015; 4(1): 1-7.
- Samango-Sprouse CA, Counts DR, Tran SL, Lasutschinkow PC, Porter GF, and Gropman AL. *Update on the Clinical Perspectives and Care of the Child with 47,XXY(Klinefelter Syndrome)*. The Application of Clinical Genetics. 2019; 12: 191–202.
- Quiroga R, Monfort S, Oltra S, Ferrer-Bolufer I, et al. *Partial Duplication of 18q Including a Distal Critical Region for Edwards Syndrome in a Patient with Normal Phenotype and Oligoasthenospermia: Case Report*. Cytogenetic and Genome Research. 2011; 133(1): 78–83.
- Chang YW, Wang PH, Li WH, et al. *Balanced and Unbalanced Reciprocal Translocation: An Overview*

al/cj41c022.pdf

of a 30-Year Experience in a Single Tertiary Medical Center in Taiwan. Journal of the Chinese Medical Association. 2013;76(3): 153–157.

26. Kosyakova N, Grigorian A, Liehr T, *et al.* *Heteromorphic Variants of Chromosome 9.* Molecular Cytogenetics. 2013;6(1): 1–11